

# Ameliorative Wound Healing Potency of Koenimbine via Attenuation of Inflammatory Cytokines in Hyperglycemia-Induced Rodent Model

Jing Xu<sup>1</sup>, Fei Wang<sup>2</sup>, Minjuan Zhang<sup>1</sup>, Maoyuan Chen<sup>1</sup>, Ke Zhao<sup>1</sup>, Yang Liu<sup>1</sup>, Dong Li<sup>1,\*</sup>

<sup>1</sup>Department of Endocrinology, Nan Jing Red Cross Hospital, Nanjing, CHINA.

<sup>2</sup>Department of Gastroenterology, Nan Jing Red Cross Hospital, Nanjing, CHINA.

## ABSTRACT

**Background:** Managing wounds in diabetic patients requires specialized approaches due to their unique healing challenges. Diabetic wounds, particularly Diabetic Foot Ulcers (DFUs), often exhibit delayed healing, increased infection risks and complications related to poor blood circulation, nerve damage and reduced immune function. Therefore, treating diabetic wounds represents a significant clinical and social concern, necessitating urgent research efforts to develop effective treatments that enhance wound healing across all dimensions. **Materials and Methods:** We investigated the bioactive compound koenimbine potency in promoting wound healing in a hyperglycemic rat model. Healthy Wistar rats were induced to have diabetes and then subjected to wound excision treatment. They were administered two different doses of koenimbine for a duration of 14 days. Glycemic and insulin levels were monitored throughout the treatment period with regular intervals. Wound diameter, percentage of wound closure, epithelization day, total collagen and protein content were measured to assess the impact of koenimbine administration of wound healing. **Results:** Free radical scavenging potency of the koenimbine on the diabetic wounds were also measured. Inflammation stimulating cytokines were quantified to evaluate the attenuating effect of koenimbine against hyperglycemia induced inflammation. The transcription factor NF- $\kappa$ B, known for promoting pro-inflammatory cytokines, along with the inflammatory mediators COX-2 and iNOS, as well as matrix metalloproteinases 2 and 9, which play a role in the degradation of extracellular matrix components, were measured to evaluate the signaling mechanisms by which koenimbine influences wound healing in diabetic rats. Koenimbine treatment effectively controlled glycemic levels and improved wound healing in diabetes-induced rats. It increased the antioxidant levels and reduced the inflammatory cytokines. Koenimbine administration inhibited the levels of NF- $\kappa$ B, COX-2, iNOS and MMP-2 and MMP-9, confirming its wound healing potency in diabetic rats. **Conclusion:** The positive impact of koenimbine was further demonstrated through our histopathological analysis of granulated wound tissue. Collectively, our findings indicate that koenimbine acts as an effective bioactive compound with the potential to enhance all three stages of diabetic wound healing.

**Keywords:** Diabetic wounds, Hyperglycemia, Impaired healing, Inflammation, Phyto drug, Koenimbine.

## Correspondence:

**Dr. Dong Li**

Department of Endocrinology, Nan Jing Red Cross Hospital, Nanjing-210000, CHINA.

Email: dongli\_628@outlook.com

**Received:** 08-11-2024;

**Revised:** 15-01-2025;

**Accepted:** 28-04-2025.

## INTRODUCTION

Diabetes, affecting an estimated 340 million individuals worldwide, poses significant health challenges, particularly in the form of diabetic wounds, which impact about 20% of patients.<sup>1</sup> By 2030, diabetes is projected to be the seventh leading cause of mortality, with high prevalence rates primarily in countries with emerging economies, where over 80% of diabetes-associated

deaths occur.<sup>2</sup> The disease disrupts glucose metabolism, leading to hyperglycemia that hampers wound healing and results in chronic issues such as foot ulcers.<sup>3</sup> Diabetic Foot Ulcers (DFU) present serious risks, including a 15% to 25% lifetime chance of occurrence and high rates of progression to severe infections or amputations. DFUs result in one amputation every 30 sec globally and have recurrence rates exceeding 50% within three years. This issue is exacerbated by inadequate preventive measures, with diabetic wounds contributing to substantial healthcare costs-approximately 2.5% to 15% of annual health budgets.<sup>4,5</sup> Since DFU treatment market projected to grow significantly, there is an urgent need for improved diagnostics and therapies to enhance patient outcomes and manage diabetic wounds effectively.



DOI: 10.5530/ijper.20251256

### Copyright Information :

Copyright Author (s) 2025 Distributed under Creative Commons CC-BY 4.0

**Publishing Partner :** Manuscript Technomedia. [www.mstechnomedia.com]

Tissue regeneration is a complex physiological mechanism aimed at restoring anatomic integrity and function following skin injury, involving overlapping phases of hemostasis, inflammation, proliferation and remodeling.<sup>6</sup> Initially, hemostasis occurs to control blood loss and prevent infection, followed by inflammation clear pathogens.<sup>7</sup> The proliferative phase involves the new tissue generation, angiogenesis and extracellular matrix to repair the wound, leading to eventual maturation and remodeling, which strengthens the tissue but often results in a scar reduced tensile strength.<sup>8</sup> This intricate healing process can be frequently disrupted by external factors given the skin's exposure to injury and such disruptions are significantly exacerbated in diabetic patients, who experience impaired inflammation and proliferation, ultimately hindering effective healing.<sup>9</sup> Diabetes significantly hinders the tissue regeneration process by impairing all four phases: hemostasis, inflammation, proliferation and remodeling, leading to enduring unfavourable impacts on day to day activities and increases mortality incidence.<sup>10,11</sup> Diabetic wounds are characterized by delayed healing, chronicity and a prolonged inflammatory phase, with incomplete or uncoordinated healing hindered by vascular damage that causes ischemia.<sup>12</sup> This impairment results from a complex interplay of factors, including vascular, neuropathic, immune and biochemical issues.<sup>13</sup> Hyperglycemia contributes to decreased vascular flexibility, disrupted circulation and impaired microcirculation, which diminishes oxygenation of tissue and impairs leukocyte migration, increasing infection susceptibility.<sup>14</sup> Diabetic foot ulcers present a complex pathology, largely driven by chronic hyperglycemia and associated issues such as impaired barrier function, elevated oxidative stress and inadequate inflammatory responses.<sup>9</sup> In contrast to nondiabetic wounds, diabetic wounds exhibit an extended pro-inflammatory state, where macrophages fail to transition effectively from inflammatory stimulating to inflammatory attenuating role, leading to excessive cytokine production and hindering the transition to healing, ultimately resulting in chronic wound formation.<sup>15,16</sup>

Phytochemicals, which are active phytoconstituents, play a significant role in wound healing owing to their wide range of pharmacological properties, such as anti-inflammatory, antioxidant and antimicrobial effects.<sup>17</sup> Phytochemicals, such as alkaloids, flavonoids, polyphenols and tannins, can modulate the inflammatory response, promote angiogenesis and enhance collagen synthesis in wound repair.<sup>18,19</sup> The integration of phytochemicals in wound healing therapies offers a promising complementary approach, potentially improving chronic wounds and also lead to novel therapeutic strategies in wound management. In this study we examined koenimbine, a carbazole alkaloid ameliorative effect on wound management in hyperglycemic rodent model.

## MATERIALS AND METHODS

### Chemicals

The major chemicals utilized in this work, such as streptozotocin, koenimbine, etc., were acquired from Sigma Aldrich, USA. The assay kits for the biochemical parameters were purchased from Thermofisher Scientific and Elabscience, USA, respectively.

### Study Animals

Healthy female Wistar rats, aged 8 weeks and weighing between 130 and 160 g, were maintained under laboratory conditions as prescribed by the animal ethics committee. The animals were housed in an environment with a relative humidity of 50-55% and a 12 hr light and dark cycle to facilitate acclimatization. During the experiment, the rats were given a rodent pellet diet and had unlimited access to food and water. The study protocol was acknowledged by Institutional Animal Ethics Committee (IAEC) after the submission of detailed protocols to be followed for the care of the rats. The procedures were conducted with care and concern for the animals.

### Hyperglycemia Induction

Hyperglycemia was triggered in female Wistar rats through a single streptozotocin shot at a dosage of approximately 70 mg/kg body weight, using a freshly prepared 0.1 M citrate buffer at pH 5. Three days after the injection, fasting blood glucose levels were assessed by collecting blood samples from the rats' orbital plexus. Wistar rats with elevated glucose levels exceeding 200 mg/dL were selected for further investigations.<sup>20</sup> The fasting blood sugar levels were quantified with OneTouch blood glucose meter.

### Establishment of Excision Wound Model

Test animals were anesthetized with 3% isoflurane before the initiation of the procedure. The dorsal skins of the anesthetized animals were shaved and the areas to excise were marked. The animals were carefully placed on the operation table in lateral position and using the sterile biopsy puncher a 10 mm circular section of full-thickness skin were excised from the marked area. The animals were returned to the home cage once recovered from anesthesia and monitored for any signs of infection and any that exhibited such signs were excluded from the study. The wound areas were measured and documented on days 1, 7 and 14 for all groups, with the measurements recorded on graph paper.

### Experimental Grouping

Test animals were grouped into four each group consisting of six rats. Group I are healthy rats which received only saline treatment throughout the experiment period. Group II are diabetic induced rats which were subjected to incision wound model and maintained throughout the treatment period without any treatment. Group III and IV are diabetic induced rats which were subjected to incision wound model and the excision wounds

were treated with topical application of 10 and 20% koenimbine respectively daily throughout the treatment period for 2 weeks. Koenimbine were prepared freshly with 0.1M DMSO before each treatment.

### Assessment of hyperglycemia

Fasting blood glucose levels in the control group, untreated hyperglycemia-induced wound-excised rats and koenimbine-treated rats were assessed using a glucose determination colorimetric kit from Thermo Fisher Scientific. Testing was conducted according to the kit's instructions and the final, pink-colored product was measured at 560 nm. Glucose concentrations in the samples were determined using a standard curve generated with beta-D-glucose standards. Additionally, serum insulin levels in the test subjects were measured using a Rat Insulin ELISA kit obtained from Invitrogen. Test samples and standards were added to ELISA plates pre-coated with insulin antibodies, followed by the addition of secondary antibodies and substrate to form an enzyme-antibody-target complex. The resulting signal intensity, which is directly proportional to insulin concentration, was measured at 450 nm within 30 min after adding the stop solution.

### Evaluation of wound closure

The wound closure rate in control and experimental rats were measured using the transparent graph paper. On day 1 a graph paper was placed the background of excised wound and the wounds were photographed to measure the size of the wound circumference in mm. The same procedure was performed on day 7 and day 14 of the treatment period. The results were recorded and percentage of the wound closure was calculated using the formula

$$\% \text{ of wound closure} = \frac{[(\text{Initial Wound Area} - \text{Current Wound Area}) / \text{Initial Wound Area}] \times 100}{1}$$

The duration taken for the dead tissue remnants to detach completely, leaving no residual raw wound or scar tissue, was recorded to measure the period of epithelization.

### Quantification of collagen

The total collagen content was estimated in the granulation tissues collected. The fat layer was carefully excised using the chloroform: methanol mixture, the mixture was prepared in 2:1 ratio. The tissue was then treated with acetone and subjected to freezing. The tissue was weighed and then processed through hydrolysis before being dried. The samples were then diluted with distilled water and the final absorbances of the hydroxyproline content in the samples were quantified at 557nm.

### Quantification of protein

Skin tissue protein levels of the wound area were quantified using the protocol of Lowry *et al.*, (1951).<sup>21</sup> The granulated tissue

was homogenized and subjected to treatment with a mixture consisting of sodium tartrate, copper sulphate and sodium carbonate. The sample was then treated with Folin-Ciocalteu reagent and incubated for 10 min at dark. The blue coloration formed was measured at 650 nm.

### Analysis of antioxidant status

#### Assessment of lipid peroxidation

The granulated tissue samples of control and experimental rats were homogenized with 10% trichloroacetic acid and the homogenate was centrifuged at 2500 rpm for 20 min at 4°C. The supernatant was collected for further quantification of MDA content. The assay was performed according to the protocol of Ohkawa *et al.*, 1979.<sup>22</sup> The samples were treated with thiobarbituric acid and subjected to heating, the MDA-TBA adducts formed were quantified at 532 nm.

#### Antioxidants quantification

SOD and CAT activities were quantified using the protocols of Nishikimi *et al.*, 1972 and Aebi, 1984.<sup>23,24</sup> Xanthine oxidase methods was used, and the superoxide radical generation inhibition was measured with nitroblue tetrazolium reduction to quantify the SOD levels in the test samples. CAT activity is quantified by monitoring the decrease in hydrogen peroxide concentration at 240 nm. Paglia and Valentine, 1967;<sup>25</sup> Habig *et al.*, 1974<sup>26</sup> protocols were used for calculating the levels of GPx and GST activity in the test samples.

#### Analysis of inflammatory response

The inflammatory stimulating cytokines TNF- $\alpha$ , IL-1 $\beta$  and IL-6 were quantified using the ELISA kit procured from Elabscience. The test samples were applied to the appropriate precoated ELISA plates and the procedure was carried out according to the kit instructions. The enzyme-substrate reaction is stopped by adding a stop solution, resulting in a yellow color change and measured OD at 450 nm.

#### Assessment of Wound Management Mechanisms

The tissue regeneration mechanism of koenimbine was evaluated by quantifying the significant molecules involved in wound healing. Nf-Kb, COX-2, iNOS and matrix metalloproteinases 2 and 9 were quantified in control and experimental animals using commercially available ELISA kits procured from MyBiosource. The test was performed as per the instructions provided in kit. Final absorbance was measured at 450 nm upon the terminating the reaction with stop solution.

#### Histopathological assessment

Granulated tissue sections collected from the control and experimental rats were incubated in formalin and subsequently processed into paraffin blocks, from which 5  $\mu$ M sections of skin were cut. Hematoxylin and Eosin (H&E) staining was done to

evaluate the cellular structure, fiber propagation and stained blood vessels. The resulting photomicrographs were examined at 40x magnification and images were captured at both wound edge and midpoint for comprehensive analysis.

### Statistical Analysis

The data are presented as mean±Standard Error of the Mean (SEM). Statistical analysis was performed using SPSS software. One-way Analysis of Variance (ANOVA) was conducted to determine the statistical differences between the treated and control groups, followed by Tukey's post hoc test for multiple comparisons. A *p*-value of less than 0.05 was considered statistically significant.

## RESULTS

### Carbazole alkaloid koenimbine promotes insulin synthesis in diabetic triggered excision wound rodent model

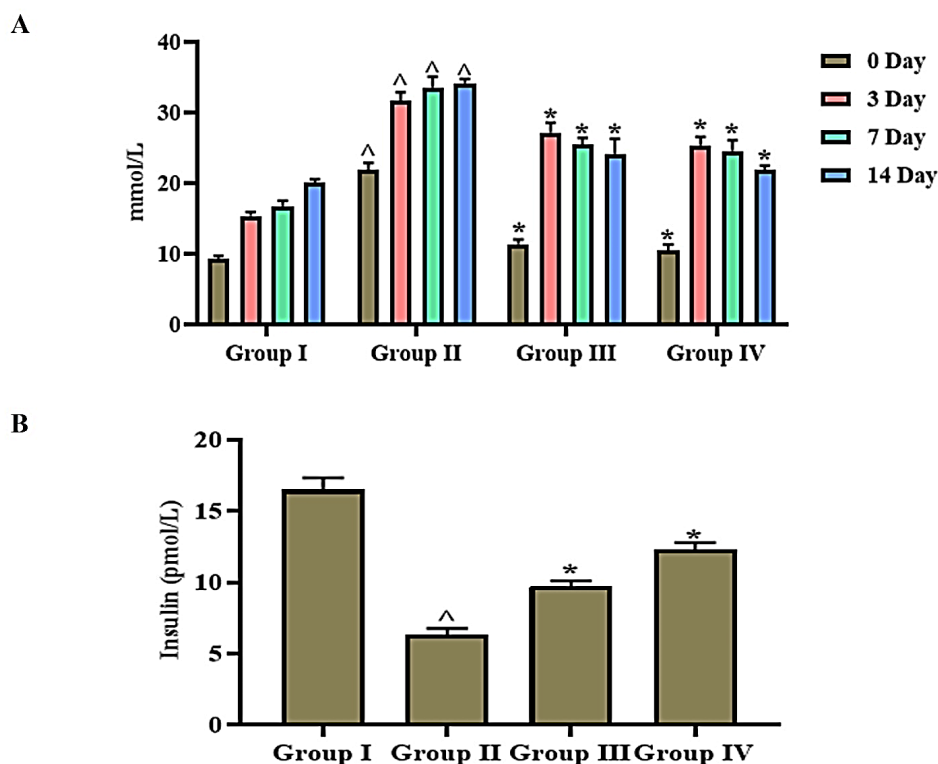
Figure 1A shows the Pre-prandial blood glucose levels of the experimental rats measured at various time points throughout the treatment period. The Pre-prandial blood glucose levels were elevated throughout the treatment period in the diabetic induced wound excised untreated rats whereas the rats treated

with koenimbine exhibited increased levels of blood glucose at the beginning phase of treatment and subsequently reduced at the end.

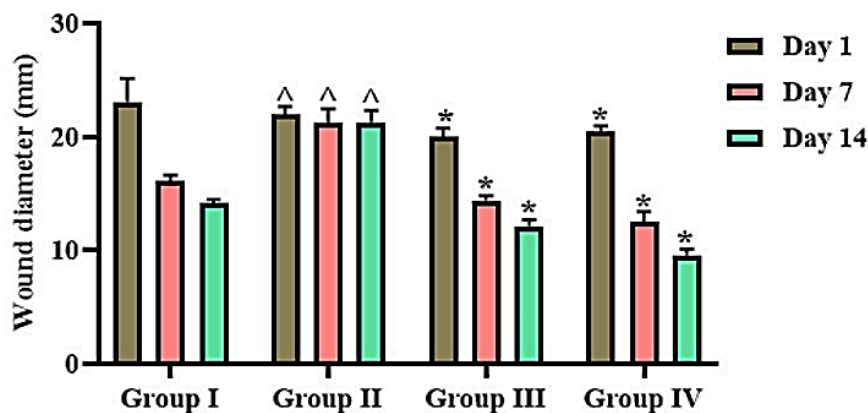
The serum insulin levels of experimental rats were quantified, and the results were illustrated in the Figure 1B. Koenimbine treatment increased the serum insulin levels to 9.4±0.0002 U/mL, 9.8±0.0002 with 10 and 20% respectively. The diabetic control rats exhibited reduced level of insulin 8.7±0.0001 U/mL compared to normal control (18±0.0002 U/mL) and koenimbine treated rats.

### Carbazole alkaloid koenimbine enhances tissue regeneration in hyperglycemia triggered excision wound rodents

Koenimbine treatment significantly enhanced the wound healing in the diabetic triggered rats. The diameter of wound was reduced in all the experimental rats compared to the diabetic control untreated the normal control saline treated rats significantly decreased wound diameter on both day 7 and 14. On day 7 the diabetic control rats exhibited increased wound diameter and it subsequently reduced on day 14 whereas the normal control exhibited considerably reduced wound diameter on day 14 (Figure 2). Koenimbine treated rats shown comparatively reduced wound diameter than the normal control and diabetic control untreated rats.



**Figure 1:** Carbazole alkaloid koenimbine promotes insulin synthesis in diabetic triggered excision wound rodent model. A) Fasting blood glucose levels quantified at 0, 3, 7 and 14<sup>th</sup> day of the treatment period. B) Serum insulin levels quantified in the normal control, diabetic control untreated, diabetic triggered 10 and 20% koenimbine treated rats. Results were presented as mean±Standard Error of the Mean (SEM). <sup>^</sup>,\**p*-value of less than 0.05 considered statistically significant.



**Figure 2:** A diameter of wound measured at different time points of treatment period (0, 7<sup>th</sup> and 14<sup>th</sup> day) in the normal control, diabetic control untreated, diabetic triggered 10 and 20% koenimbine treated rats. Results were presented as mean±Standard Error of the Mean (SEM). ^,\*p-value of less than 0.05 considered statistically significant.

70-75% of wound closure was recorded in normal control and hyperglycemic control untreated rodents whereas koenimbine treatment increased the wound closure percentage to 80-85% in 14 days of treatment period (Figure 3A). The period of epithelization was decreased with koenimbine treatment than diabetic control untreated rats. The epithelization was comparatively lower in the normal control rats than the koenimbine treated rats (Figure 3B). Koenimbine treatment had increased both the total collagen and protein in diabetic rats. 10% koenimbine treated rats exhibited 0.84 ± 0.0002 mg/100 mg of dry tissue of total collagen and 5.2 ± 0.001 mg/100 mg of dry tissue of total protein. The total collagen and protein content were increased to 0.92 ± 0.0003 and 5.2 ± 0.001 mg/100 mg of dry tissue with 20% koenimbine treatment. Diabetic triggered untreated rats shown decreased levels of total collagen (0.75 ± 0.0002 mg/100 mg of dry tissue) and protein (4.8 ± 0.001 mg/100 mg of dry tissue) compared to the control rats total collagen (0.97 ± 0.0003 mg/100 mg of dry tissue) and protein levels (6.2 ± 0.001 mg/100 mg of dry tissue) (Figures 3C and D).

### Carbazole alkaloid koenimbine enhances antioxidant status in diabetic triggered excision wound rodent model

Figure 4A illustrates MDA content in the experimental rats. Hyperglycemic control untreated rats shown significantly enhanced levels of MDA content compared to the control and koenimbine treated rats. Koenimbine treatment significantly scavenged oxidative stress and MDA levels were decreased in both 10 and 20% koenimbine treated rats compared to the diabetic control untreated rats. Koenimbine treatment significantly enhanced the levels of both SOD and CAT which are the vital antioxidant enzymes that crucial role in tissue regeneration by managing oxidative stress. It enhanced GST and GPx levels, critical enzymes involved in the wound healing which effectively repairs wound and promote tissue regeneration with

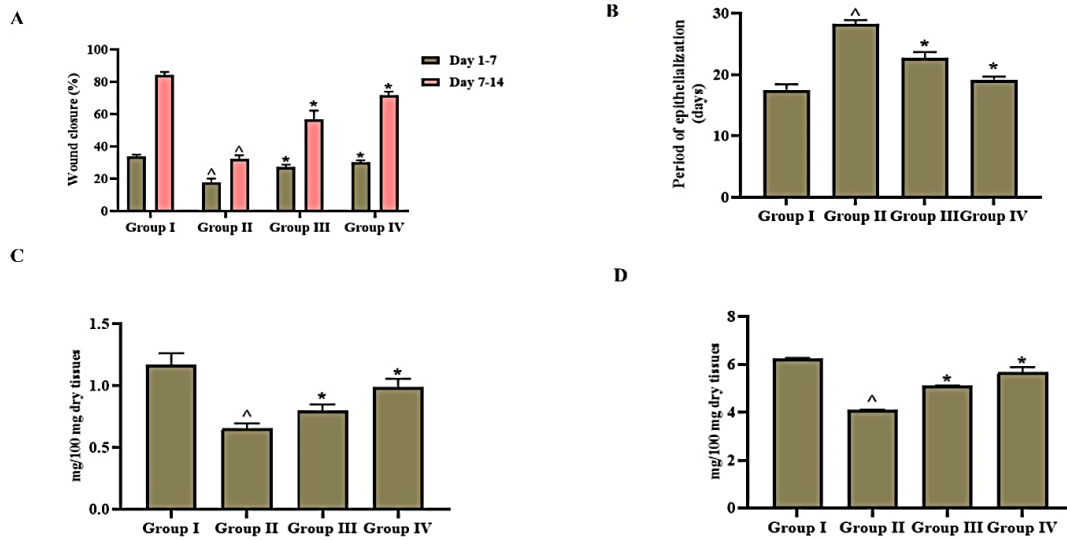
their antioxidant and detoxifying properties. The antioxidants levels were significantly reduced in the hyperglycemic control untreated rats. The healthy control rats exhibited significantly higher levels of antioxidants than the diabetic control untreated and koenimbine treated (Figure 4B).

### Carbazole alkaloid koenimbine attenuates inflammatory response in diabetic triggered excision wound rodent model

Cytokines are crucial in orchestrating the intricate interactions involved in inflammation, immune responses and tissue repair, making them vital for effective wound healing. In diabetic control rats that were not treated, levels of pro-inflammatory cytokines, including Tumor Necrosis Factor-alpha (TNF-α), Interleukin-1 beta (IL-1β) and Interleukin-6 (IL-6), were significantly higher compared to the other experimental groups. In contrast, treatment with koenimbine resulted in a marked decrease in these pro-inflammatory cytokine levels among diabetic rats when compared to the untreated diabetic control group, although the cytokine levels were still elevated relative to those in the normal control rats (Figure 5).

### Carbazole alkaloid koenimbine promotes wound healing signaling in diabetic triggered excision wound rodent model

The wound excision in hyperglycemic induced rats left untreated promotes the synthesis of transcription factor NF-κB which enhances pro-inflammatory cytokines expression. The COX-2 and iNOS the inflammatory mediators involved in tissue damage were also increased in the untreated rats. Koenimbine treatment had significantly lowered the NF-κB, COX-2 and iNOS in the hyperglycemic triggered rats. The levels of matrix metalloproteinases MMP-2 and MMP-9, which play a role in the breakdown of extracellular matrix components, were also significantly reduced following treatment with koenimbine.



**Figure 3:** Carbazole alkaloid koenimbine enhances wound healing in diabetic triggered excision wound rodent model. A) Wound closure percentage B) Epithelization period C) Total collagen content D) Total protein content quantified in the normal control, diabetic control untreated, diabetic triggered 10 and 20% koenimbine treated rats. Results were presented as mean±Standard Error of the Mean (SEM). <sup>△</sup>,\**p*-value of less than 0.05 considered statistically significant.

Hyperglycemic control untreated rats shown significantly enhanced MMP-2 and MMP-9 levels compared to the control and koenimbine treated rats (Figure 6).

### Carbazole alkaloid koenimbine effectively ameliorated excision wound in diabetic triggered rats

Figure 7 depicts the H&E stained representative images of granulated tissue section of control and experimental rats. Diabetic control untreated group exhibited thin layer of epithelium with increased infiltration of neutrophils (7B). Decreased fibroblasts and blood vessels were observed in the hyperglycemic control untreated group than the other experimental rats. Koenimbine treatment increased the fibroblast and collagen fibers, it also thickened epithelium of wound tissue. Compared to 10% koenimbine treated group (7C), 20% koenimbine treated rats shown significantly elevated levels of epithelium and fibroblast (7D). The infiltrations of neutrophils were decreased and epithelium layer was increased in control group than the diabetic triggered untreated group rats (7A).

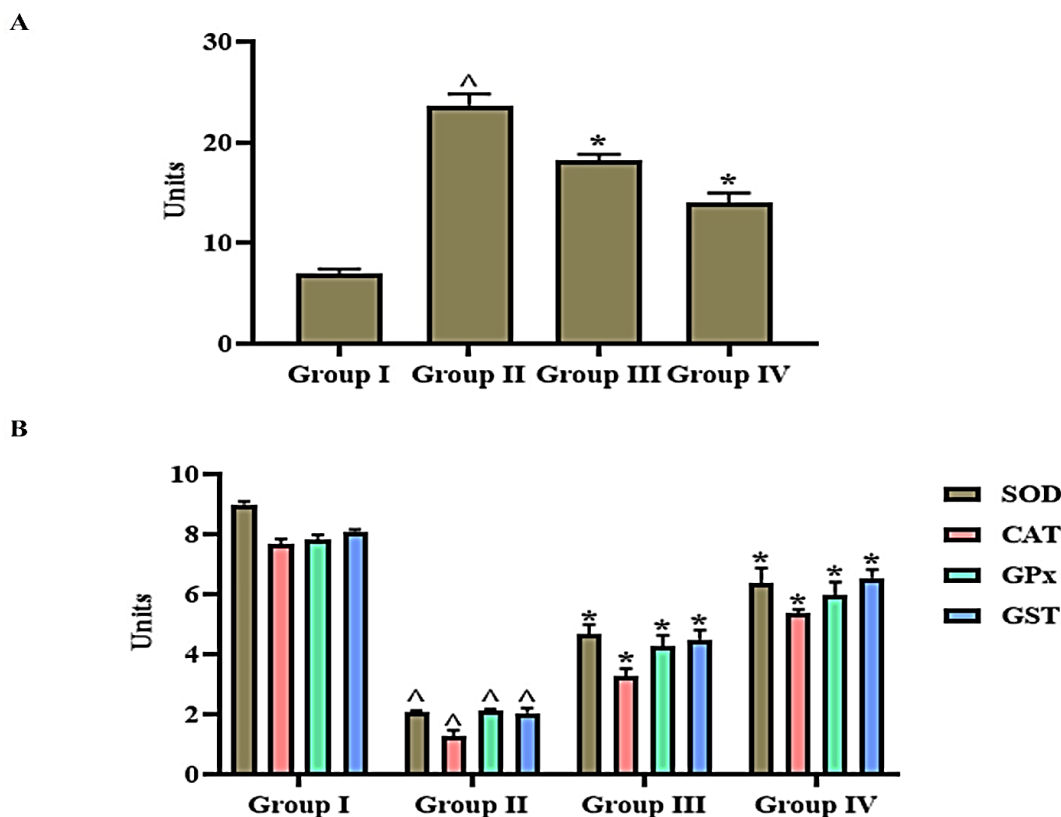
## DISCUSSION

Herbal therapy, the use of plant-derived substances for therapeutic purposes, has garnered increasing global attention as a viable alternative or complement to conventional medicine. Many cultures have relied on herbal remedies for centuries and recent scientific research has validated the efficacy of various herbal therapies in managing various health conditions. Approximately 80% of the world population depends on traditional medicine, as evidenced by the \$19.4 billion revenue generated from herbal

remedies in 2010.<sup>27</sup> Requirement for ethanomedicine is rising, with India's and China's market growing annually by 20%.<sup>28,29</sup>

*Murraya koenigii* (L.) Spreng, generally recognized as curry leaves belongs to the Rutaceae family and is widely found in South Asia.<sup>30</sup> Rich in phytochemicals, particularly carbazole alkaloids, *M. koenigii* has demonstrated pharmacological activities, including anti-microbial, anti-cancer,<sup>31,32</sup> anti-inflammatory and anti-oxidant effects.<sup>33</sup> Notably, koenimbine, a specific carbazole alkaloid found in the plant, has been studied for its diverse therapeutic potential.<sup>34</sup> The aim of this study was to assess the effectiveness of the bioactive compound koenimbine in treating diabetic-related wounds.

Tissue regeneration involves four overlapping stages: hemostasis, inflammation, proliferation and remodeling. In hemostasis, a platelet plug quickly forms to stop bleeding. During inflammation, immune cells clear debris and prevent infection. In the proliferation phase, fibroblasts and endothelial cells aid in tissue repair, collagen formation and angiogenesis. Lastly, the remodeling phase strengthens and reorganizes the tissue enhancing wound integrity.<sup>35,36</sup> In diabetic condition all the three phases of wound healing are reported to be impaired. Hyperglycemia prolongs the inflammatory phase, hinders angiogenesis, impairs the endothelial progenitor cells function and causes dysregulation of extracellular matrix.<sup>37,38</sup> Therefore, managing hyperglycemia is crucial for treating wounds in diabetic patients. In this context, we investigated the efficacy of koenimbine in regulating hyperglycemia in diabetic rodent model. Treatment with koenimbine significantly enhanced insulin synthesis in diabetic rats and lowered their glycemc levels.



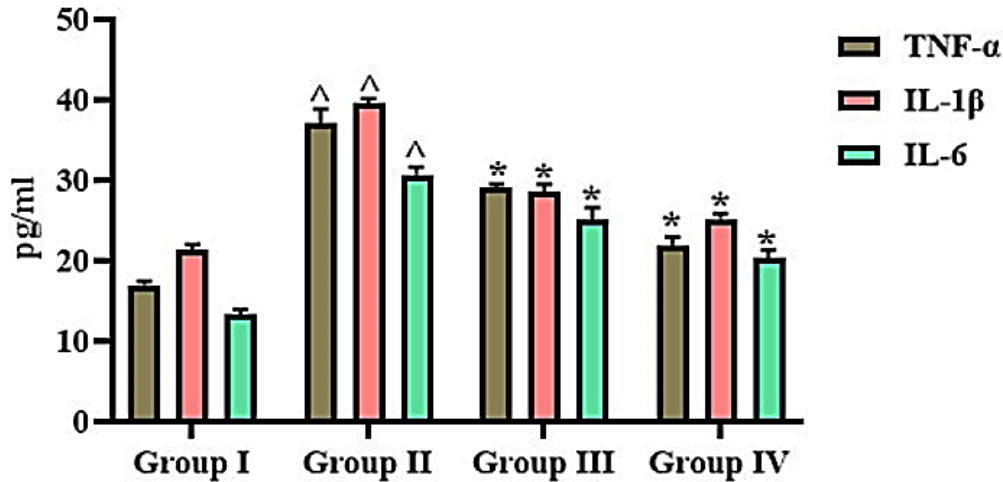
**Figure 4:** Carbazole alkaloid koenimbine enhances antioxidant status in diabetic triggered excision wound rodent model. A) Lipid Peroxidation-MDA content B) Antioxidants-SOD, CAT, GPx and GST levels in the normal control, diabetic control untreated, diabetic triggered 10 and 20% koenimbine treated rats. Results were presented as mean±Standard Error of the Mean (SEM). ^,\*p-value of less than 0.05 considered statistically significant. Units: nmol/mg protein.

Reactive Oxygen Species (ROS) play a vital role in regulating multiple phases of wound healing. While low levels of ROS are necessary for combating external damage, an overload of oxidative stress in tissues, coupled with a reduced antioxidant response, contributes to a redox imbalance, significantly affecting the healing of diabetic wounds.<sup>39</sup> Clinical studies have shown that chronic diabetic wounds are often characterized by a highly oxidizing environment, which correlates with conditions such as hyperglycemia and tissue hypoxia.<sup>40</sup> Treatment with *M. koenigii* extracts had reported to decrease oxidative stress in diabetic pancreatic cells.<sup>41</sup> It also scavenged free radicals attenuated lipid peroxidation in liver cells induced with ethanol toxicity<sup>42</sup> and cardiac cells induced cadmium induced oxidative stress.<sup>43</sup> In our study, koenimbine, a primary carbazole alkaloid found in *M. koenigii*, significantly increased antioxidant levels and mitigated oxidative stress, thereby reducing lipid peroxidation in rats induced with diabetes.

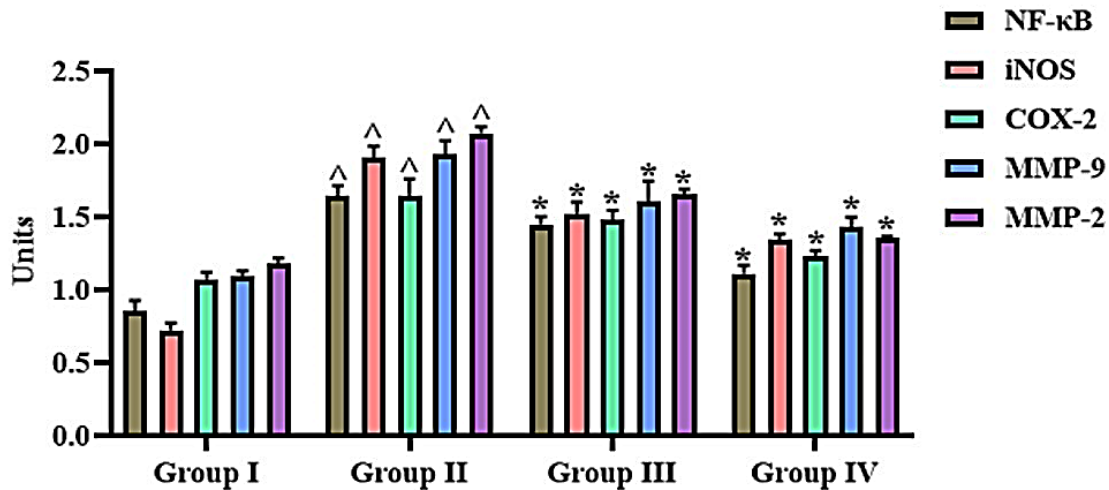
Diabetic wounds tend to remain in the inflammatory phase much longer than non-diabetic wounds, leading to delayed healing and often resulting in chronic wounds.<sup>44</sup> In normal wound healing, pro-inflammatory M1 macrophages eventually shift to the anti-inflammatory M2 phenotype, which promotes extracellular matrix formation and new blood vessel growth.<sup>45</sup>

However, in diabetic wounds, macrophages produce excessive pro-inflammatory cytokines and the transition from M1 to M2 macrophages is disrupted.<sup>46</sup> Research shows that persistent high blood glucose levels activate the NF-κB signaling pathway, increasing the production of AGEs and promoting the release of cytokines. This triggers a continuous inflammatory cycle dominated by M1 macrophages, which release cytokines that attract additional monocytes and encourage further M1 polarization. This imbalance between M1 and M2 macrophages prolongs the inflammatory stage, preventing the wound from progressing to the proliferative phase necessary for healing.<sup>47</sup> Therefore preventing the M1 and M2 imbalance and preventing the extent inflammatory phase in wound healing the prime target for treating diabetes wounds. Our results had confirmed koenimbine treatment had attenuated the synthesis of inflammatory stimulating cytokines TNF alpha, IL-6 and IL-1β in diabetic triggered rats. This may be due to inhibition of NFκB, transcription factor which prevented the synthesis of inflammatory cytokines.

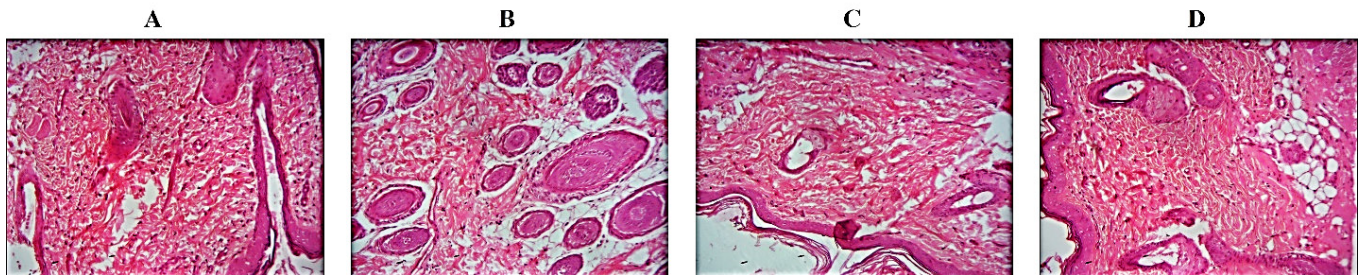
iNOS and COX-2 contribute to wound healing by promoting vascularization, inflammation and immune response, but their regulation must be balanced to avoid excessive inflammation and tissue damage, which can impede the tissue regeneration.<sup>48,49</sup>



**Figure 5:** Carbazole alkaloid koenimbine attenuates inflammatory response in diabetic triggered excision wound rodent model. Pro-inflammatory cytokines-Tumor Necrosis Factor-alpha (TNF-α), Interleukin-1 beta (IL-1β) and Interleukin-6 (IL-6) levels in the normal control, diabetic control untreated, diabetic triggered 10 and 20% koenimbine treated rats. Results were presented as mean±Standard Error of the Mean (SEM). <sup>△</sup>, \**p*-value of less than 0.05 considered statistically significant.



**Figure 6:** Carbazole alkaloid koenimbine promotes wound healing signaling in diabetic triggered excision wound rodent model. NF-κB, COX-2, iNOS, MMP2 and MMP9 levels in the normal control, diabetic control untreated, diabetic triggered 10 and 20% koenimbine treated rats. Results were presented as mean±Standard Error of the Mean (SEM). <sup>△</sup>, \**p*-value of less than 0.05 considered statistically significant.



**Figure 7:** Carbazole alkaloid koenimbine effectively ameliorated excision wound in diabetic triggered rats. Representative images of H&E stained granulated tissue sections. A) Normal control, B) Diabetic control untreated, C) Diabetic triggered 10% koenimbine treated rats, D) Diabetic triggered 20% koenimbine treated rats. 40X magnification.

Previous research had reported administration of celecoxib enhanced the healing of pressure ulcers by lowering the expression of iNOS and COX-2. This reduction had helped to decrease wound inflammation and supports dermal reconstruction and scar formation.<sup>50</sup> Koenimbine treatment also attenuated the synthesis of iNOS and COX-2 which confirms its potency of ameliorating diabetic wounds. Our examination of wound throughout the treatment and the histopathological examination of granulated tissue further confirms koenimbine had effectively alleviated the diabetic wound via scavenging the free radicals and preventing prolonged inflammatory phase.

Matrix Metalloproteinases (MMPs), particularly MMP-1 and MMP-9, are essential for keratinocyte migration, which is a key step in wound re-epithelialization.<sup>51</sup> MMP-1 aids this process by interacting with  $\alpha 2\beta 1$  integrin on type I collagen, while MMP-9 is responsible for type IV and type VII collagen break down, which form part of the basement membrane. This collagen degradation facilitates keratinocyte movement and helps restore the wound surface.<sup>52</sup> In healthy tissue, MMP-9 levels were reduced but increases following injury; however, prolonged MMP-9 expression in long-lasting wounds can impede repairing. Proper regulation of MMP-9 is therefore crucial for effective re-epithelialization.<sup>53</sup> In diabetic conditions, elevated glucose levels can disrupt MMP expression by enhancing glycation and maintaining high levels of inflammatory cytokines, which disrupts the extracellular matrix components essential for tissue regeneration.<sup>54</sup> Koenimbine treatment in diabetes-triggered wounds inhibited the synthesis of MMP-1 and MMP-9 while increasing collagen and protein synthesis, thereby enhancing wound healing in diabetic rats. Our examination confirms that koenimbine administration positively affected all three phases of wound healing and effectively alleviated diabetic wounds.

## CONCLUSION

In conclusion, the findings from this study demonstrate that koenimbine is a potent bioactive compound for enhancing wound healing in diabetic-induced rat models. By effectively managing glycemic levels and improving wound healing outcomes, koenimbine showcases its potential to promote all three phases of the healing process. The significant reductions in inflammatory cytokines and key mediators associated with the inflammatory response, such as NF- $\kappa$ B, COX-2, iNOS and MMPs, further underscore its therapeutic efficacy. Additionally, the supportive histopathological evidence reinforces the beneficial impact of koenimbine on granulated wound tissue. Therefore, koenimbine may serve as a promising candidate for the treatment of diabetic wounds, warranting further research and development to translate these findings into clinical practice.

## ACKNOWLEDGEMENT

This work was supported by Department of Endocrinology, Nan Jing Red Cross Hospital, Nanjing, 210000, China.

## CONFLICT OF INTEREST

The authors declare that there is no conflict of interest.

## ABBREVIATIONS

**DFU:** Diabetic foot ulcers; **WHO:** World Health Organization; **ROS:** Reactive oxygen species; **AGE:** Advanced glycation end products; **MMPs:** Matrix metalloproteinases.

## ETHICAL APPROVAL

This work has approved by the institutional animal ethical committee by Department of Endocrinology, Nan Jing Red cross Hospital, Nanjing, 210000, China.

## SUMMARY

Diabetic wounds are characterized by delayed healing, chronicity and a prolonged inflammatory phase, with incomplete or uncoordinated healing hindered by vascular damage that causes ischemia. koenimbine, a specific carbazole alkaloid found in the plant, has been studied for its diverse therapeutic potential. koenimbine, a primary carbazole alkaloid found in *M. koenigii*, significantly increased antioxidant levels and mitigated oxidative stress, thereby reducing lipid peroxidation in rats induced with diabetes

## REFERENCES

- Hossain MJ, Al-Mamun M, Islam MR. Diabetes mellitus, the fastest growing global public health concern: early detection should be focused. *Health Sci Rep.* 2024; 7(3): e2004. doi: 10.1002/hsr2.2004, PMID 38524769.
- Sun H, Saeedi P, Karuranga S, Pinkepank M, Ogurtsova K, Duncan BB, et al. IDF Diabetes Atlas: global, regional and country-level diabetes prevalence estimates for 2021 and projections for 2045. *Diabetes Res Clin Pract.* 2022; 183: 109119. doi: 10.1016/j.diabres.2021.109119, PMID 34879977.
- Patel S, Srivastava S, Singh MR, Singh D. Mechanistic insight into diabetic wounds: pathogenesis, molecular targets and treatment strategies to pace wound healing. *Biomed Pharmacother.* 2019; 112: 108615. doi: 10.1016/j.biopha.2019.108615, PMID 30784919.
- Armstrong DG, Boulton AJ, Bus SA. Diabetic foot ulcers and their recurrence. *N Engl J Med.* 2017; 376(24): 2367-75. doi: 10.1056/NEJMra1615439, PMID 28614678.
- Chang M, Nguyen TT. Strategy for treatment of infected diabetic foot ulcers. *Acc Chem Res.* 2021; 54(5): 1080-93. doi: 10.1021/acs.accounts.0c00864, PMID 33596041.
- Wallace HA, Basehore BM, Zito PM. Wound healing phases. In: *Treasure Island, (FL): StatPearls Publishing; 2023 Jun 12. StatPearls [Internet].* p. 2024 Jan-. PMID 29262065.
- Zhao R, Liang H, Clarke E, Jackson C, Xue M. Inflammation in chronic wounds. *Int J Mol Sci.* 2016; 17(12): 2085. doi: 10.3390/ijms17122085, PMID 27973441.
- Singh MR, Saraf S, Vyas A, Jain V, Singh D. Innovative approaches in wound healing: trajectory and advances. *Artif Cells Nanomed Biotechnol.* 2013; 41(3): 202-12. doi: 10.3109/21691401.2012.716065, PMID 23316788.
- Burgess JL, Wyant WA, Abdo Abujamra B, Kirsner RS, Jozic I. Diabetic wound-healing science. *Medicina (Kaunas).* 2021; 57(10): 1072. doi: 10.3390/medicina57101072, PMID 34684109.
- Alavi A, Sibbald RG, Mayer D, Goodman L, Botros M, Armstrong DG, et al. Diabetic foot ulcers: Part I. Pathophysiology and prevention. *J Am Acad Dermatol.* 2014; 70(1): 1.e1-18; quiz 19. doi: 10.1016/j.jaad.2013.06.055, PMID 24355275.
- Maffi P, Secchi A. The burden of diabetes: emerging data. *Dev Ophthalmol.* 2017; 60: 1-5. doi: 10.1159/000459641, PMID 28427059.
- Greenhalgh DG. Wound healing and diabetes mellitus. *Clin Plast Surg.* 2003; 30(1): 37-45. doi: 10.1016/s0094-1298(02)00066-4, PMID 12636214.

13. Galkowska H, Wojewodzka U, Olszewski WL. Chemokines, cytokines and growth factors in keratinocytes and dermal endothelial cells in the margin of chronic diabetic foot ulcers. *Wound Repair Regen.* 2006; 14(5): 558-65. doi: 10.1111/j.1743-6109.2006.00155.x, PMID 17014667.
14. Okonkwo UA, DiPietro LA. Diabetes and wound angiogenesis. *Int J Mol Sci.* 2017; 18(7): 1419. doi: 10.3390/ijms18071419, PMID 28671607.
15. Boniakowski AE, Kimball AS, Jacobs BN, Kunkel SL, Gallagher KA. Macrophage-mediated inflammation in normal and diabetic wound healing. *J Immunol.* 2017; 199(1): 17-24. doi: 10.4049/jimmunol.1700223, PMID 28630109.
16. Davis FM, Kimball A, Boniakowski A, Gallagher K. Dysfunctional wound healing in diabetic foot ulcers: new crossroads. *Curr Diabetes Rep.* 2018; 18: 1-8.
17. Shah A, Amini-Nik S. The role of phytochemicals in the inflammatory phase of wound healing. *Int J Mol Sci.* 2017; 18(5): 1068. doi: 10.3390/ijms18051068, PMID 28509885.
18. Majewska J, Gendaszewska-Darmach E. Proangiogenic activity of plant extracts in accelerating wound healing—a new face of old phytomedicines. *Acta Biochim Pol.* 2011; 58(4): 449-60. doi: 10.18388/abp.2011\_2210, PMID 22030557.
19. Thangapazham RL, Sharad S, Maheshwari RK. Phytochemicals in wound healing. *Adv Wound Care (New Rochelle).* 2016; 5(5): 230-41. doi: 10.1089/wound.2013.0505, PMID 27134766.
20. Chen XY, Jiang WW, Liu YL, Ma ZX, Dai JQ. Anti-inflammatory action of geniposide promotes wound healing in diabetic rats. *Pharm Biol.* 2022; 60(1): 294-9. doi: 10.1080/13880209.2022.2030760, PMID 35130118.
21. Lowry OH, Rosebrough NJ, Farr AL, Randall RJ. Protein measurement with the Folin phenol reagent. *J Biol Chem.* 1951; 193(1): 265-75. doi: 10.1016/S0021-9258(19)52451-6, PMID 14907713.
22. Ohkawa H, Ohishi N, Yagi K. Assay for lipid peroxides in animal tissues by thiobarbituric acid reaction. *Anal Biochem.* 1979; 95(2): 351-8. doi: 10.1016/0003-2697(79)90738-3, PMID 36810.
23. Nishikimi M, Appaji NA, Yagi K. The occurrence of superoxide anion in the reaction of reduced phenazine methosulfate and molecular oxygen. *Biochem Biophys Res Commun.* 1972; 46(2): 849-54. doi: 10.1016/s0006-291x(72)80218-3, PMID 4400444.
24. Aebi H. Catalase *in vitro*. *Method Enzymol.* 1984; 105: 121-6. doi: 10.1016/s0076-6879(84)05016-3, PMID 6727660.
25. Paglia DE, Valentine WN. Studies on the quantitative and qualitative characterization of erythrocyte glutathione peroxidase. *J Lab Clin Med.* 1967; 70(1): 158-69. PMID 6066618.
26. Habig WH, Pabst MJ, Jakoby WB. Glutathione S-transferases: the first enzymatic step in mercapturic acid formation. *J Biol Chem.* 1974; 249(22): 7130-9. doi: 10.1016/S0021-9258(19)42083-8, PMID 4436300.
27. Ujowundu CO, Okafor OE, Agha NC, Nwaogu LA, Igwe KO, Igwe CU. Phytochemical and chemical composition of *Combretum zenkeri* leaves. *J Med Plants Res.* 2010; 4(10): 965-8.
28. Kang W, Wang Y. China digital governance development review over the past two decades. *Int J Public Admin.* 2018; 5(3): 92-106. doi: 10.4018/IJPA.2018070107.
29. Andrade C, Gomes NG, Duangsrirai S, Andrade PB, Pereira DM, Valentão P. Medicinal plants utilized in Thai Traditional Medicine for diabetes treatment: ethnobotanical surveys, scientific evidence and phytochemicals. *J Ethnopharmacol.* 2020; 263: 113177. doi: 10.1016/j.jep.2020.113177, PMID 32768637.
30. Handral HK, Pandith A, Shruthi SD. A review on *Murraya koenigii*: multipotential medicinal plant. *Asian J Pharm Clin Res.* 2012; 5(4): 5-14.
31. Ahmadipour F, Noordin MI, Mohan S, Arya A, Paydar M, Looi CY, et al. Koenimbine, a natural dietary compound of *Murraya koenigii* (L) Spreng: inhibition of MCF7 breast cancer cells and targeting of derived MCF7 breast cancer stem cells (CD44(+)/CD24(-/low)): an *in vitro* study. *Drug Des Dev Ther.* 2015; 9: 1193-208. doi: 10.2147/DDDT.S72127, PMID 25759564.
32. Astaneh M, Ghafouri-Fard S, Fazeli Z, Taherian-Esfahani Z, Dashti S, Motevaseli E. Assessment of anti-cancer effects of koenimbine on colon cancer cells. *Hum Antibodies.* 2020; 28(3): 185-90. doi: 10.3233/HAB-200405, PMID 32116245.
33. Balakrishnan R, Vijayaraja D, Jo SH, Ganesan P, Su-Kim I, Choi DK. Medicinal profile, phytochemistry and pharmacological activities of *Murraya koenigii* and its primary bioactive compounds. *Antioxidants (Basel).* 2020; 9(2): 101. doi: 10.3390/antiox9020101, PMID 31991665.
34. Singh S, Ahuja A, Murti Y, Khaliq A. Phyto-Pharmacological Review on *Murraya koenigii* (L.) Spreng: as an Indigenous Plant of India with High Medicinal Potential. *Chem Biodivers.* 2023; 20(7): e202300483. doi: 10.1002/cbdv.202300483, PMID 37269458.
35. Stadelmann WK, Digenis AG, Tobin GR. Physiology and healing dynamics of chronic cutaneous wounds. *Am J Surg.* 1998; 176(2A Suppl):265-385. doi: 10.1016/s0002-9610(98)00183-4, PMID 9777970.
36. Eming SA, Martin P, Tomic-Canic M. Wound repair and regeneration: mechanisms, signaling and translation. *Sci Transl Med.* 2014; 6(265): 265sr6. doi: 10.1126/scitranslmed.3009337, PMID 25473038.
37. Spampinato SF, Caruso GI, De Pasquale R, Sortino MA, Merlo S. The treatment of impaired wound healing in diabetes: looking among old drugs. *Pharmaceuticals (Basel).* 2020; 13(4): 60. doi: 10.3390/ph13040060, PMID 32244718.
38. Mieczkowski M, Mrozkiewicz-Rakowska B, Kowara M, Kleibert M, Czupryniak L. The problem of wound healing in diabetes: from molecular pathways to the design of an animal model. *Int J Mol Sci.* 2022; 23(14): 7930. doi: 10.3390/ijms23147930, PMID 35887276.
39. Dunnill C, Patton T, Brennan J, Barrett J, Dryden M, Cooke J, et al. Reactive oxygen species (ROS) and wound healing: the functional role of ROS and emerging ROS-modulating technologies for augmentation of the healing process. *Int Wound J.* 2017; 14(1): 89-96. doi: 10.1111/iwj.12557, PMID 26688157.
40. Cano Sanchez M, Lancel S, Boulanger E, Neviere R. Targeting oxidative stress and mitochondrial dysfunction in the treatment of impaired wound healing: a systematic review. *Antioxidants (Basel).* 2018; 7(8): 98. doi: 10.3390/antiox7080098, PMID 30042332.
41. Arulselvan P, Subramanian SP. Beneficial effects of *Murraya koenigii* leaves on antioxidant defense system and ultra structural changes of pancreatic  $\beta$ -cells in experimental diabetes in rats. *Chem Biol Interact.* 2007; 165(2): 155-64. doi: 10.1016/j.cbi.2006.10.014, PMID 17188670.
42. Sathaye S, Bagul Y, Gupta S, Kaur H, Redkar R. Hepatoprotective effects of aqueous leaf extract and crude isolates of *Murraya koenigii* against *in vitro* ethanol-induced hepatotoxicity model. *Exp Toxicol Pathol.* 2011; 63(6): 587-91. doi: 10.1016/j.etp.2010.04.012, PMID 20488686.
43. Khan BA, Abraham A, Leelamma S. Anti-oxidant effects of curry leaf, *Murraya koenigii* and mustard seeds, *Brassica juncea* in rats fed with high fat diet. *Ind J Exp Biol.* 1997; 35(2): 148-50. PMID 9315222.
44. Zhao R, Liang H, Clarke E, Jackson C, Xue M. Inflammation in chronic wounds. *Int J Mol Sci.* 2016; 17(12): 2085. doi: 10.3390/ijms17122085, PMID 27973441.
45. Dasari N, Jiang A, Skochdopole A, Chung J, Reece EM, Vorstenbosch J, et al. Updates in diabetic wound healing, inflammation and scarring. *Semin Plast Surg.* 2021 Aug; 35(3): 153-8. doi: 10.1055/s-0041-1731460, PMID 34526862.
46. Davis FM, Kimball A, Boniakowski A, Gallagher K. Dysfunctional wound healing in diabetic foot ulcers: new crossroads. *Curr Diabetes Rep.* 2018; 18: 1-8.
47. Yadav JP, Verma A, Pathak P, Dwivedi AR, Singh AK, Kumar P, et al. Phytoconstituents as modulators of NF- $\kappa$ B signalling: investigating therapeutic potential for diabetic wound healing. *Biomed Pharmacother.* 2024; 177: 117058. doi: 10.1016/j.biopha.2024.117058, PMID 38968797.
48. Shi HP, Most D, Efron DT, Tantry U, Fischel MH, Barbul A. The role of iNOS in wound healing. *Surgery.* 2001; 130(2): 225-9. doi: 10.1067/msy.2001.115837, PMID 11490353.
49. Lopes FB, Sarandy MM, Novaes RD, Valacchi G, Gonçalves RV. OxInflammatory responses in the wound healing process: a systematic review. *Antioxidants (Basel).* 2024; 13(7): 823. doi: 10.3390/antiox13070823, PMID 39061892.
50. Romana-Souza B, Dos Santos JS, Bandeira LG, Monte-Alto-Costa A. Selective inhibition of COX-2 improves cutaneous wound healing of pressure ulcers in mice through reduction of iNOS expression. *Life Sci.* 2016; 153: 82-92. doi: 10.1016/j.lfs.2016.04.017, PMID 27091651.
51. Gooyit M, Peng Z, Wolter WR, Pi H, Ding D, Heseck D, et al. A chemical biological strategy to facilitate diabetic wound healing. *ACS Chem Biol.* 2014; 9(1): 105-10. doi: 10.1021/cb4005468, PMID 24053680.
52. Li Z, Guo S, Yao F, Zhang Y, Li T. Increased ratio of serum matrix metalloproteinase-9 against TIMP-1 predicts poor wound healing in diabetic foot ulcers. *J Diabetes Complications.* 2013; 27(4): 380-2. doi: 10.1016/j.jdiacomp.2012.12.007, PMID 23357650.
53. Fang WC, Lan CE. The epidermal keratinocyte as a therapeutic target for management of diabetic wounds. *Int J Mol Sci.* 2023; 24(5): 4290. doi: 10.3390/ijms24054290, PMID 36901720.
54. Jones JI, Nguyen TT, Peng Z, Chang M. Targeting MMP-9 in diabetic foot ulcers. *Pharmaceuticals (Basel).* 2019; 12(2): 79. doi: 10.3390/ph12020079, PMID 31121851.

**Cite this article:** Xu J, Wang F, Zhang M, Chen M, Zhao K, Liu Y, Li D. Ameliorative Wound Healing Potency of Koenimbine via Attenuation of Inflammatory Cytokines in Hyperglycemia-Induced Rodent Model. *Indian J of Pharmaceutical Education and Research.* 2025;59(4):1419-28.