

Hydroalcoholic *Carthamus tinctorius* L. Extract Attenuates TNBS-induced Ulcerative Colitis in Mice Via Downregulation of Inflammation and Oxidative Stress

Zhongbao Niu¹, Li Zhang^{2,*}

¹Department of Traditional Chinese Medicine, Shandong Provincial Hospital (Affiliated to Shandong First Medical University), Jinan, Shandong, CHINA.

²Department of Anorectal, The People's Hospital of Huaiyin, Jinan, Shandong, CHINA.

ABSTRACT

Background: Ulcerative colitis (UC) is distinct by severe inflammation of intestinal epithelial tissue and more than 2 million people worldwide are affected with ulcerative colitis. This disease is primarily driven by oxidative stress and inflammation. **Objectives:** To identify a safer remedy with less/no adverse effect, we investigated the beneficial ability of *Carthamus tinctorius* L. extracts to alleviate multi-factorial conditions like oxidative stress, lipid peroxidation, and inflammation in Trinitro benzenesulfonic acid induced experimental ulcerative colitis in mice. **Materials and Methods:** Ulcerative colitis in Balb/c mice were induced by intrarectal administration of TNBS. Hydroalcoholic *Carthamus tinctorius* L. extracts were supplemented orally and all mice were observed and scored for clinical manifestations. After sacrificing mice, inflammatory markers, colonic oxidative stress levels, and antioxidant enzymes were measured. Histological features of the colon were also analyzed. **Results:** Supplementing the TNBS-induced group with the plant extracts suppressed oxidative stress, enhanced cytoprotective antioxidants, and reduced inflammation. The histological evaluation also showed restoration of damaged tissues. **Conclusion:** Our findings indicate the curative ability of the hydroalcoholic *Carthamus tinctorius* L. extracts and can be a good therapeutic candidate to treat Ulcerative colitis. **Keywords:** Ulcerative colitis, TNBS, *Carthamus tinctorius* L., Oxidative stress, Inflammation.

INTRODUCTION

Inflammation is a physiopathology process mediated by several signaling molecules namely pro-inflammatory cytokines. Inflammatory bowel disease (IBD) is a chronic, life-threatening, and relapsing gastroenteric inflammatory disease. Ulcerative colitis (UC) and Crohn's disease (CD) are the subtypes of IBD. Ulcerative colitis is characterized by intestinal ulceration, epithelial damage, and mucosal inflammation. The incidence and prevalence of UC worldwide are substantially increasing¹ but still etiology of UC remains unclear.² However, we know that an abnormal mucosal immune response triggers an inflammatory milieu that attracts neutrophils, activates the release of reactive

oxygen species, reactive nitrogen species, and several proinflammatory cytokines. The milieu causes tissue damage and plays a critical role in the pathogenesis of ulcerative colitis.³

Ulcerative colitis is an inflammatory idiopathic disease with no treatment to prevent the origin of the disease.⁴ Current treatment options include corticosteroids, Anti-TNF agents, immuno-suppressants, and monoclonal antibodies. Although some of these treatments have been effective, they have several adverse effects associated with them.⁵ Approaches based on using complementary medicine to treat UC have been described to be effective.⁶⁻⁸

Submission Date: 25-02-2022;

Revision Date: 03-04-2022;

Accepted Date: 02-05-2022.

DOI: 10.5530/ijper.56.3.128

Correspondence:

Mrs. Li Zhang

Department of Anorectal,
The People's Hospital of
Huaiyin, Jinan, Shandong,
250021, CHINA.

E-mail: zhangll2021@sina.com



www.ijper.org

Carthamus tinctorius L. commonly known as safflower belongs to the family Asteraceae and is widely cultivated in Southern Asia. Currently, more than 200 compounds have been isolated. Some of these active compounds include alkaloids, quinolones, flavonoids, polyacetylene, safflower polysaccharides, and organic acids,⁹⁻¹⁰ with pharmacological effects such as anti-inflammatory, antioxidant, antinociceptive, hepatoprotective, and immunomodulating properties.¹¹⁻¹⁵ Considering the bioactive compounds, we aim to investigate the therapeutic potential of *Carthamus tinctorius* L. against TNBS-induced ulcerative colitis in balb/c mice.

MATERIALS AND METHODS

Plant extract preparation

The dried powder of *Carthamus tinctorius* L. was immersed in 70% ethanol (200g/l) at room temperature for 48 hr with occasional stirring. After 48 hr, the hydroalcoholic extract was filtered using a Whatman filter paper and the ethanolic solution was evaporated at 40°C. The dried extract was stored at 4°C until use.

Animals

36 female Balb/c mice weighing 25 - 30 g and aged between 8 - 10 weeks were chosen for the experiments. These mice were acclimatized for 14 days in the laboratory before the commencement of the experiment. The animals were maintained at a relative humidity of 50-55% and temperature 22-24°C with a 12 hr light/dark cycle. Normal drinking water and the commercially available pellet were given as a diet. The maintenance and experiments were performed in accordance with the National Institutes of Health guide for the care and use of laboratory animals approved by the Shandong Provincial Hospital Ethics Committee (Approval code: SDFMU202202C05).

TNBS Induction and experimental design

36 Balb/c mice were divided into 6 groups and placed in separate cages. The hydroalcoholic *Carthamus tinctorius* L. extracts were given in varying concentrations (100, 200, and 300 mg/kg). Trinitrobenzenesulfonic Acid (TNBS) was used as an agent to induce ulcerative colitis. Prior to induction, the mice were starved for a day with access to drinking water. Isoflurane was used to anesthetize and then a mixture of 100 µL of 5% TNBS and absolute ethanol (1:1 ratio) was intrarectally administered using a catheter. After administration, the mice were held vertically for 2-3 min for better distribution of TNBS. The treatment was given for 6 days and the mice were euthanized using a higher dose of isoflurane on

the 7th day. The timeline is illustrated in Figure 1. The colon was used for further experiments and given to histopathological analysis. The experiment groups were:

- Group 01: Control group.
- Group 02: Vehicle group, Intrarectal administration of 100 µL 50% ethanol.
- Group 03: Induced group, Intrarectal administration of 50 µL 5% TNBS + 50 µL absolute ethanol.
- Group 04: Treated group, TNBS-induced mice orally administered with 100 mg/kg of *Carthamus tinctorius* L. extract.
- Group 05: Treated group, TNBS-induced mice orally administered with 200 mg/kg of *Carthamus tinctorius* L. extract.
- Group 06: Treated group, TNBS-induced mice orally administered with 300 mg/kg of *Carthamus tinctorius* L. extract.

Clinical assessment of colitis

The mice in all 6 groups were observed daily for clinical manifestations of colitis such as changes in body weight, bloody stool, and stool consistency. Based on these manifestations, a disease activity index (DAI) score ranging from 0-12 is given (Table 1) as described by Hidalgo-Cantabrana *et al.*¹⁶

Colonic macroscopic damage and ulcer score assessment

After euthanization, the entire lower gastrointestinal tract was removed. The colon was identified, separated, and opened longitudinally. The luminal content was removed using normal saline. The weight and length of the mice colon were measured using a weighing balance and a ruler respectively for measuring the colonic macroscopic

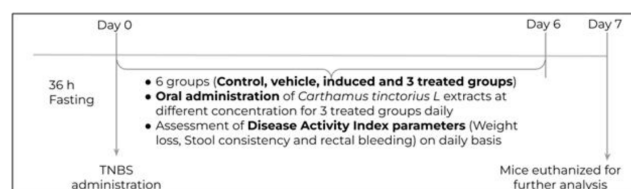


Figure 1: Experimental timeline.

Table 1: Disease Activity Index (DAI) score.

Score	% weight loss	Stool consistency	Rectal bleeding
0	None	Normal	No bleeding
1	1-5%	-	-
2	5-10%	Loose stool	Slight bleeding
3	10-15%	-	-
4	>15%	Watery diarrhea	Gross bleeding

Table 2: Ulcer scoring method.

Score	Observation
0	No damage
1	Localized hyperemia with no ulcers
2	Linear ulcer with no significant inflammation
3	Linear ulcer with inflammation at one site
4	Linear ulcer with inflammation, the size of ulcer
5	Multiple inflammations and ulcers, the size of ulcer >1 cm

damage (CMD).¹⁷ The CMD was calculated using the formula:

$$\text{CMD} = \frac{\text{Weight of the colon (mg)}}{\text{Length of the colon (cm)}}$$

To measure colonic ulcer scores, noticeable damages in the distal colon were examined and scored from 0-5 based on the extent of colonic damage (Table 2) as described by Zeng *et al.*¹⁸

Biochemical assays

Different antioxidant and oxidative stress parameters such as MPO, LPO, NO, SOD, and GSH were evaluated.

MPO activity assay

Myeloperoxidase (MPO) assay was performed according to Kim *et al.*¹⁹ The colonic tissues were weighed and homogenized in an ice-cold 50 mM Potassium Phosphate buffer (pH 6.0) containing 0.5% Cetyltrimethylammonium bromide (CTAB). The tissue homogenate is then mixed with O-dianisidine, 50 mM Potassium Phosphate buffer, and diluted H₂O₂. A yellow compound is formed and it is spectrophotometrically measured 3 times at 450 nm at 30-sec intervals. MPO activity was determined and expressed in U/mg of tissue.

Nitric oxide (NO) estimation

The amount of NO in the colon sample was estimated using the protocol given in Tarpey *et al.*²⁰ Nitric oxide determination is performed colorimetrically by estimating the decomposition of nitrite (NO₂⁻) to nitrate (NO₃⁻). Nitrate is determined using Griess reagent. The Griess reagent is 2% Sulfonamide and 0.2% (w/v) Naphthalene ethylenediamine dissolved in 5% (v/v) Phosphoric acid. When nitrate reacts with Griess reagent it produces an azo dye product that has an absorption maxima of 540 nm. The obtained absorbance value is compared to the standard graph and the final nitric oxide concentration is expressed in μmols/mg of protein.

Malondialdehyde (MDA) assay

Lipid peroxidation assay of the mice colon tissue was performed based on the method of Leon *et al.*²¹ with slight modifications. MDA is a primary indication of lipid peroxidation (LP) as it is a secondary product of LP. When a molecule of MDA reacts with 2 molecules of a chromogenic reagent, 2-thiobarbituric acid in an acidic environment it yields a pink-colored compound that has an absorption maxima of 532 nm. Malondialdehyde is measured in μmols/mg of protein.

Superoxide dismutase (SOD) activity

Superoxide dismutase is an antioxidant enzyme that predominantly scavenges superoxides. The SOD in the tissue sample reacts with Nitro Blue Tetrazolium and reduces it to give a blue compound that has a 560 nm absorption maxima. The activity of SOD is given in terms of the percentage of product formation. This assay is followed based on the protocol given by Saggu *et al.*²²

Reduced glutathione (GSH) activity

Glutathione is a key antioxidant that mostly exists in reduced form GSH. Reduced glutathione was determined by the method described by Pippenger *et al.*²³ Colon tissues were homogenized in a potassium phosphate buffer (10 mM). 1-chloro-2, 4-dinitrobenzene (CDNB) was added to the tissue homogenate. CDNB is a substrate that conjugates with GSH present in the sample to form a conjugate that has an absorption maxima at 340 nm. GST is measured in terms of free sulfhydryls (mM).

Statistical analysis

The results from the experiments are expressed in the mean ± standard deviation (SD). *P* value less than 0.001 was considered significant. Statistical analysis was carried out using one-way ANOVA (Tukey multiple comparison tests). The graphs were plotted using GraphPad Prism 5 software (GraphPad Software Inc., San Diego, CA, USA).

RESULTS

Extracts of *C. tinctorius* L. ameliorates complication of colitis

The clinical features of the TNBS mice model are weight loss, bloody stool, and diarrhea. DAI evaluation includes all the aforementioned features and assesses the severity of inflammation. The data in (Figure 2) demonstrates the change in body weight. TNBS induced groups had significant loss of weight up to 15% compared to the normal mice which had no weight loss. Treatment with *C. tinctorius* extracts showed a reduction in body weight loss at doses 200 and 300 mg/kg compared to 100 mg/kg.

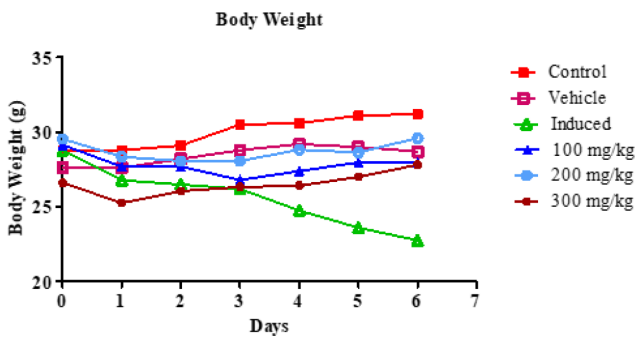


Figure 2: *Carthamus tinctorius* L. extract reduced the loss of weight whereas the TNBS induced groups showed significant weight loss.

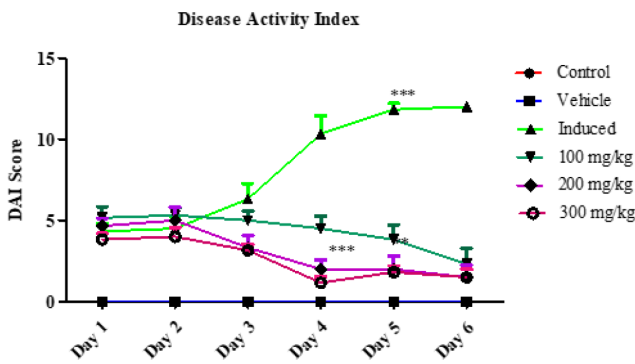


Figure 3: The effects of *Carthamus tinctorius* L. extract on clinical parameters of UC. The DAI index significantly reduced with increase in the dosage. Results are expressed as mean \pm SD. Treated groups showed high significance compared to induced group ($P < 0.0001$).

The DAI increased to a maximum of 12 in the induced group on day 7 compared to the control. After administering *C. tinctorius* extracts of doses 100, 200, and 300 mg/kg the DAI decreased to 2.3 ± 0.94 , 1.5 ± 0.76 , and 1.5 ± 0.5 respectively as shown in (Figure 3).

Alleviation of colonic macroscopic damage and ulcers scores:

The weight of the colon was higher and the length was shortened upon TNBS induction. This increased the colonic macroscopic damage score to 1.75 ± 0.006 compared to the control groups which had a score of 0.073 ± 0.03 . The CMD scores were significantly lower (0.100 ± 0.003) in the highest dose of *C. tinctorius* extracts (300 mg/kg) when compared to the other two doses. Thus, this extract prevents the increase in CMD induced by TNBS (Figure 4).

Ulcer scores were evaluated based on the degree of damage as shown in Table 2. The control and vehicle groups had no macroscopic ulceration. However, UC induction using TNBS caused a significant increase in the score up to 3.66 ± 0.74 . This score was dropped to

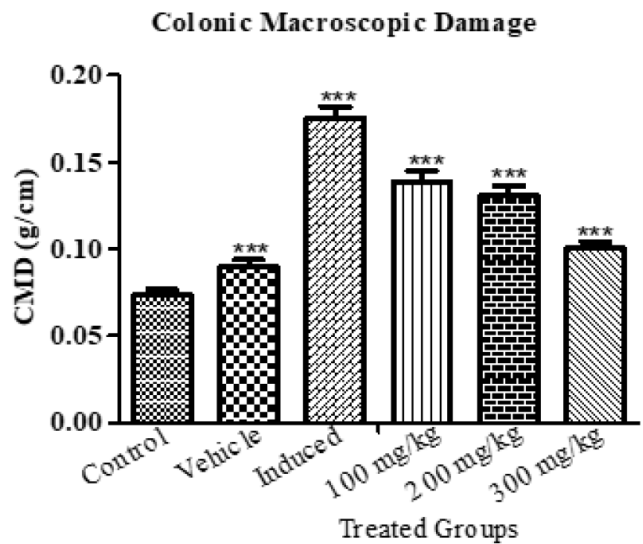


Figure 4: Effect *Carthamus tinctorius* L. on colon weight and length. The CMD of the treated groups showed high significance compared to induced group ($P < 0.0001$). Results are expressed as mean \pm SD.

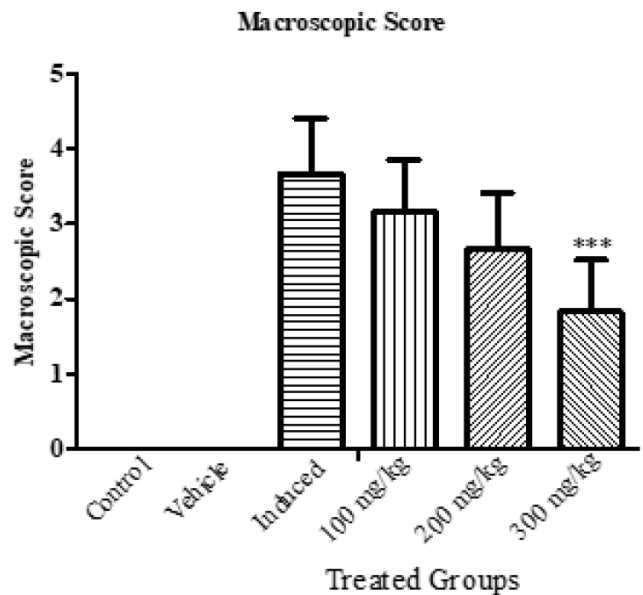


Figure 5: Reduction of ulcer macroscopic scores on administering *Carthamus tinctorius* L. extracts with higher significance ($P < 0.0001$). Results are expressed as mean \pm SD.

3.16 ± 0.68 , 2.66 ± 0.68 , and 1.83 ± 0.68 on administering hydroalcoholic extracts of *C. tinctorius* L. as visualized in Figure 5.

***C. tinctorius* L. extracts mitigates oxidative stress and inflammation**

The effect of TNBS induced and treated groups on inflammatory and oxidative stress markers such as MPO, NO, and LPO were evaluated and depicted in Figures 6, 7, and 8 respectively. Compared to the control

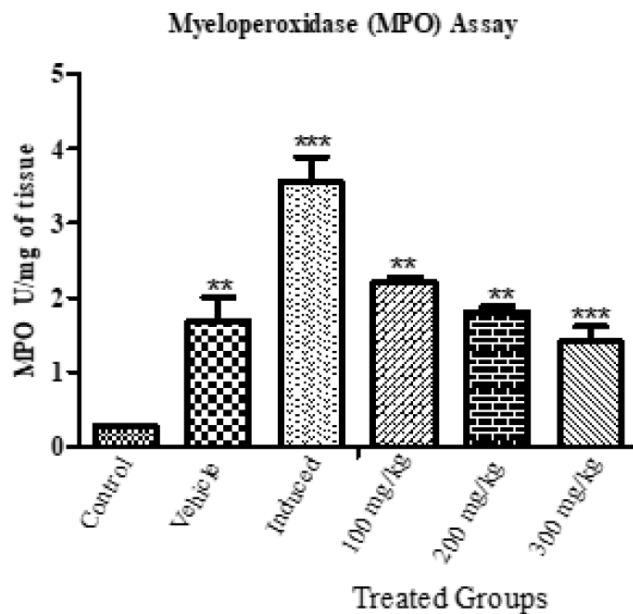


Figure 6: Myeloperoxidase estimation between control, vehicle, induced and *Carthamus tinctorius* L. extracts treated groups were studied. MPO level of treated groups was significantly decreased when compared to induced group. Treated groups showed high significance compared to control ($P < 0.0001$).

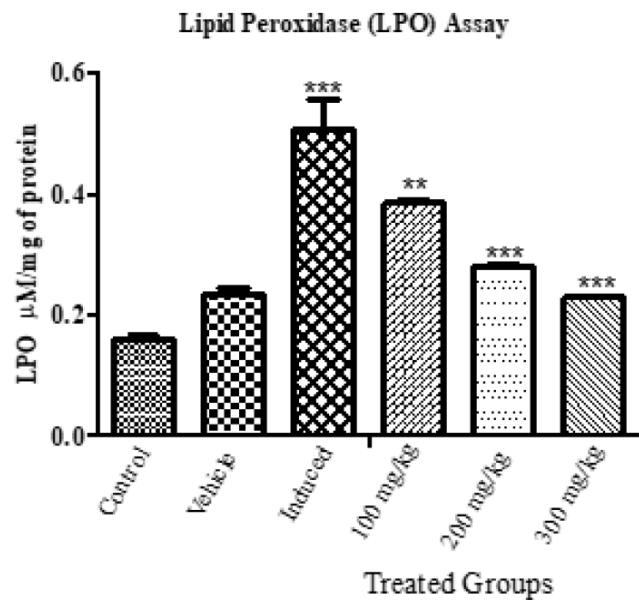


Figure 8: Lipid peroxidation estimation between control, vehicle, induced and *Carthamus tinctorius* L. extracts treated groups. LPO level of treated groups was significantly decreased when compared to induced group and showed high significance compared to control ($P < 0.0001$).

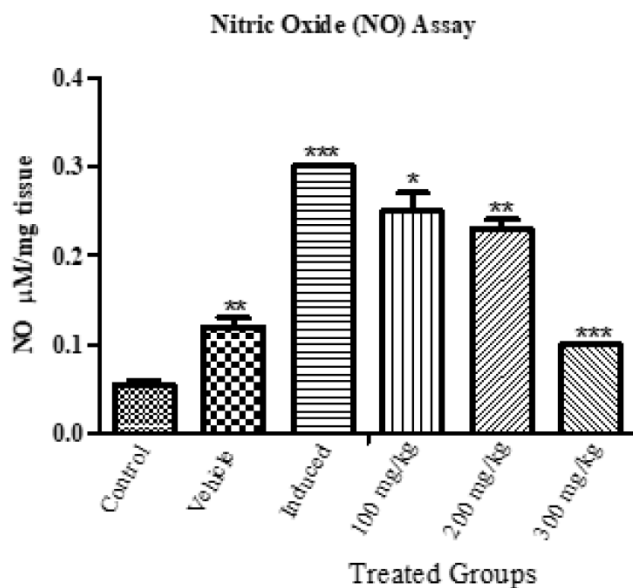


Figure 7: Effect of *Carthamus tinctorius* L. extracts on nitric oxide levels of treated groups at different doses. NO level of treated groups was significantly decreased when compared to induced group and also showed high significance compared to control ($P < 0.0001$).

group (0.268), the MPO levels in induced groups were significantly higher (3.55 ± 0.33). On treating the induced group with the extract of *C. tinctorius* L. the elevation of MPO levels was controlled significantly with mean values of 2.212 ± 0.067 , 1.81 ± 0.067 U/mg of tissue, and 1.40 ± 0.20 for doses 100, 200, and 300 mg/kg.

The extract of *C. tinctorius* L. cause a significant decrease in the nitric oxide levels compared to the induced group. The NO levels in TNBS induced group was 0.3 whereas at doses 100, 200, and 300 mg/kg resulted in the destruction of nitric oxide levels to 0.25 ± 0.02 , 0.23 ± 0.01 , and $0.1 \mu\text{mol}/\text{mg}$ of protein respectively. Similar to MPO and NO, TNBS elevated MDA levels from 0.16 ± 0.005 to 0.50 ± 0.04 . *C. tinctorius* L. extract showed a dose-dependent suppression. Mild decrease was seen in 100 mg/kg ($0.38 \pm 0.005 \mu\text{mol}/\text{mg}$ of protein) while 200 and 300 mg/kg showed a moderate decrease in MDA levels (0.27 ± 0.003 , and $0.23 \pm 0.001 \mu\text{mol}/\text{mg}$ of protein).

Extracts of *C. tinctorius* L. improves antioxidant enzymes activity

The enzyme activity of the cytoprotective antioxidants such as SOD and GSH were evaluated. TNBS significantly suppressed the SOD enzyme activity (Control group: $148.6 \pm 0.53\%$; Induced group: $66.99 \pm 0.63\%$). *C. tinctorius* L. treated groups showed a dose-dependent increase in the SOD activity with mean values of 79.06 ± 0.33 , 84.25 ± 0.36 , and $107.68 \pm 0.71\%$ for doses 100, 200, and 300 mg/kg respectively as illustrated in Figure 9.

The GSH level in the mice tissue of the TNBS induced group was significantly lower ($0.029 \pm 0.002 \text{ mM}$) than that of the control group ($0.133 \pm 0.003 \text{ mM}$). However, administering doses of 100, 200, and 300 mg/kg of

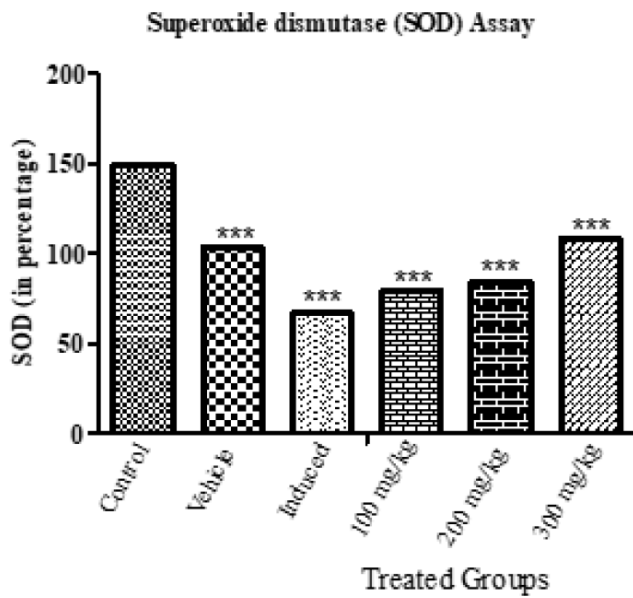


Figure 9: Effect of *Carthamus tinctorius* L. extracts on SOD level of control, induced and treated. Results are expressed as mean \pm SD. Treated groups showed high significance compared to control ($P < 0.0001$).

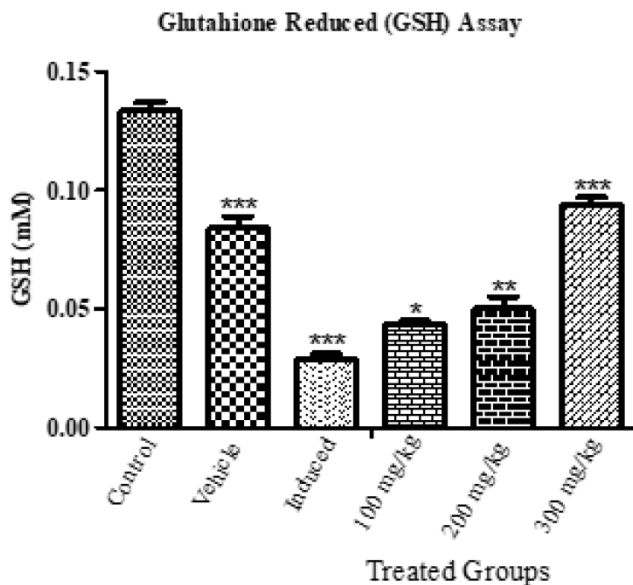


Figure 10: Glutathione reduced estimation between control, induced and *Carthamus tinctorius* L. extracts treated groups. GSH level of treated groups was significantly increased when compared to induced group. Treated groups showed high significance compared to control ($P < 0.0001$).

C. tinctorius L. resulted in an elevation of GSH levels to 0.043 ± 0.001 , 0.05 ± 0.005 , and 0.094 ± 0.003 mM respectively as shown in Figure 10.

Histopathological evaluation of colon

Sections of the colon from the control group mice showed normal histological structures with the normal architecture of the epithelium, submucosa, lamina

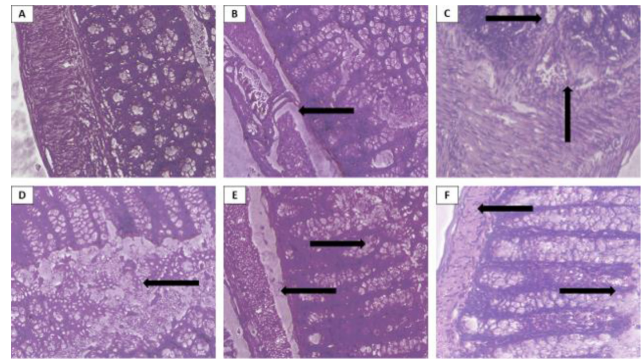


Figure 11 (A-F): Histopathological analysis of mice colonic tissues. (A) – Control group showing normal architecture with colon structures preserved. (B) – Vehicle group which received ethanol showing mucosal barrier break an indicated by the black arrow. (C) – TNBS induced group showing ulceration and immune cells infiltration. (D) – TNBS-induced and treated with 100 mg/kg showing slight signs of recovery from tissue damage. (E) – TNBS-induced and treated with 200 mg/kg show reduced infiltration and visible recovery. (F) – TNBS-induced and treated with 300 mg/kg showing restoration of the damaged intestinal cells and a similar architecture to the control group.

propria with no infiltration of immune cells (Figure 11A). Damage to the colonic mucous layer is observed in the vehicle group which received 50% ethanol intrarectally. Other than the mucosal layer damage, no significant tissue damage was seen (Figure 11B). In contrast, TNBS administered groups resulted in a drastic loss of tissue structure, erosion of epithelium, and elevation in immune cells infiltration as seen in Figure 11C. The treated groups showed gradual restoration of the lost tissue architecture with the increase in the dosage of *C. tinctorius* L. extract. On treatment with 200 mg/kg showed a reduction in infiltrated immune cells and recovery of the mucosal damage Figure 11E. Attenuation of tissue injury was observed in the maximum dose of 300 mg/kg (Figure 11F).

DISCUSSION

New therapeutic strategies for ulcerative colitis are being developed with new findings. However, corticosteroids are the preferred option for patients with severe UC and it is associated with irreversible adverse effects.^{5,24} Therefore, an appropriate treatment strategy with minimal/no adverse effects is important.

In our current study, the major objective was to assess the ameliorative efficacy of the hydroalcoholic *Carthamus tinctorius* L. extract against ulcerative colitis and its complications. Trinitrobenzenesulfonic acid (TNBS) induced mice model was used as it elicits a cellular immune response, induces inflammation in the gastrointestinal tracts, and has similar histopathological

and morphological features to human IBD.²⁵ In the following days after intrarectal TNBS induction, symptoms associated with colitis such as weight loss, diarrhea, and bloody stool were observed and scored. These scores along with the increased score of colonic macroscopic damage and ulcer strongly indicate an inflammatory milieu and severe tissue damage. Administering the extracts of *Carthamus tinctorius* L. reversed the tissue damage, reduced inflammation, and prevented excess loss of nutrients as the diarrhea was controlled in higher doses. All of these effects reduced the scores and it is evident that *Carthamus tinctorius* has strong inflammatory properties as shown in previous studies.^{11,15}

Myeloperoxidase (MPO) is a pro-inflammatory enzyme found in azurophilic granules of neutrophils. The MPO activity estimates the oxidative stress in and correlates with the content of neutrophils in the mice's colonic tissue.²⁶ This assay is used as a severity index of gastroenteric inflammation. Relative to the control group the TNBS induced group has elevated levels of oxidative stress and immune cells infiltration. Accumulation of immune cells can lead to granulocyte-mediated mucosal barrier damage.²⁷ Supplementation of hydroalcoholic extract of *C. tinctorius* L. reduced MPO activity. An increase in dosage caused a decrease in the activity of MPO, this suggests the reduction in inflammation and oxidative stress.

Lipid peroxidation is an indicator of oxidative stress. LPO is induced in the presence of free radicals and results in oxidative deterioration of membrane components, especially polyunsaturated lipids. This process causes DNA damage and cellular death. MDA is an indicator of LPO that is produced during the breakdown of lipids.²⁸ TNBS induced groups showed marked elevation in MDA levels showing the presence of more oxidative radicals. However, after treating the mice with the *C. tinctorius* L. extracts the MDA levels were reversed. The reversal effect of LPO might be because of the flavonoids in the plant and they are known to inhibit the chain reaction in LPO.²⁹

We measured the cellular nitric oxide (NO) levels and the exposure to TNBS markedly increased NO levels compared to the control group. NO is a small molecule that has anti-inflammatory effects in normal physiological conditions but under abnormal situations, it is known to be a pro-inflammatory mediator and induces inflammation.³⁰ NO plays a vital role in the pathogenesis of UC by forming highly reactive molecules such as dinitrogen trioxide and peroxy nitrite that causes colonic mucosal damage and ulcer formation via ROS generation.^{31,32} The increase in NO levels was attenuated

by *C. tinctorius* L. hydroalcoholic extract treatment. This finding corroborates with the MPO results and further potentiates the anti-inflammatory effects of the extract. The chief enzymes involved in defense against ROS-mediated injuries are superoxide dismutase enzymes (SOD). This enzyme is for maintaining the redox balance.³³ An imbalance causes oxidative stress that has a critical function in inducing mucosal injury and GIT inflammation in UC.³⁴ SOD reduces superoxides (O_2^-) to water (H_2O) thereby scavenging free radicals. The TNBS induced group has lower SOD and elevated superoxides. On treating the induced group with *C. tinctorius* L. extract the SOD levels increased suggesting the restoration of oxidative balance in the colon.

GSH is a hydrophilic antioxidant enzyme. It plays a vital role in preventing oxidative stress-associated tissue damage after UC induction. UC is associated with an increased generation of ROS. Higher production of ROS exhausts the GSH concentration.³⁵ This reduction indicates that oxidative stress is progressive in the GI milieu.³⁶ TNBS administration depleted the amount of GSH and increased oxidative stress. On treatment with hydroalcoholic extract of *C. tinctorius* L., notably upregulated the GSH contents. This might be because the extracts might have lowered the ROS that reduced the progression of oxidative stress.

Histological evaluation of the colonic tissue showed structural distortion in the TNBS-induced groups. The microarchitecture was restored on treating the induced group with hydroalcoholic extract of *Carthamus tinctorius* L. Histological alteration on administering TNBS includes ulceration, epithelial erosion, depletion of intestinal tissues such as goblet cells. These damages may be induced by oxidative stress. Only ethanol was intrarectally administered in the vehicle group. Ethanol is also known as a "mucosal barrier breaker" causing damage in the mucosal layer³⁷⁻³⁸ as visualized in the histopathology results. TNBS also induced infiltration of immune cells causing inflammatory alterations. At dose 200 mg/kg, the degree of ulceration is reduced compared to induced group and at dose 300 mg/kg, almost normal histology of goblet cells can be visualized. Treatment *C. tinctorius* showed signs of colon tissue recovery and reduced immune cells influx suggesting the ameliorative role of *Carthamus tinctorius* L. Our results suggest that the hydroalcoholic *Carthamus tinctorius* L. extract is able to reduce the progression of TNBS-induced colitis in mice by regulating the inflammatory process and restoring the role of antioxidant enzymes such as SOD, and GSH. Further investigation is required to understand the mechanism of *Carthamus tinctorius* L. extract on amelioration of UC.

CONCLUSION

The data from this study demonstrate the remedial effect of hydroalcoholic *Carthamus tinctorius* L. extract against TNBS-induced ulcerative colitis. This extract reduced the DAI scores, colonic macroscopic damage, and ulcer scores. It also improved the activity of the antioxidant enzymes, attenuated lipid peroxidation, suppressed oxidative stress, and reduced immune cells infiltration. These results strongly suggest the protective effects of *Carthamus tinctorius* L. extract and could have therapeutic potential for the treatment of ulcerative colitis.

ACKNOWLEDGEMENT

The authors would like to thank The People's Hospital of Huaiyin, Jinan for their support.

CONFLICT OF INTEREST

The authors declare that there is no conflict of interest.

ABBREVIATIONS

UC: Ulcerative Colitis; **TNBS:** Trinitrobenzenesulfonic acid; **IBD:** Inflammatory bowel disease; **CD:** Crohn's disease; **DAI:** Disease activity index; **CMD:** Colonic macroscopic damage; **MPO:** Myeloperoxidase; **CTAB:** Cetyltrimethylammonium bromide; **NO:** Nitric oxide; **MDA:** Malondialdehyde; **LP:** lipid peroxidation; **SOD:** Superoxide dismutase; **GSH:** Reduced glutathione; **SD:** Standard deviation; **ANOVA:** Analysis of variance; **CMD:** Colonic microscopic damage; **LPO:** Lipid peroxidation; **ROS:** Reactive Oxygen species; **GI:** Gastro Intestinal; **C. tinctorius:** *Carthamus tinctorius* L.

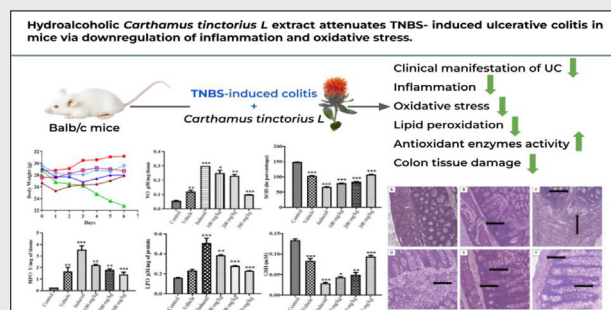
REFERENCES

- Du L, Ha C. Epidemiology and pathogenesis of ulcerative colitis. *Gastroenterol Clin North Am.* 2020;49(4):643-54. doi: 10.1016/j.gtc.2020.07.005, PMID 33121686.
- Zakerska-Banaszak O, Tomczak H, Gabryel M, Baturo A, Wolko L, Michalak M, et al. Dysbiosis of gut microbiota in Polish patients with ulcerative colitis: A pilot study. *Sci Rep.* 2021;11(1):2166. doi: 10.1038/s41598-021-81628-3. PMID 33495479.
- Porter RJ, Kalla R, Ho GT. Ulcerative colitis: Recent advances in the understanding of disease pathogenesis. *F1000Research.* 2020;9. doi: 10.12688/f1000research.20805.1, PMID 32399194.
- Tatiya-Aphiradee N, Chatuphonprasert W, Jarukamjorn K. Immune response and inflammatory pathway of ulcerative colitis. *J Basic Clin Physiol Pharmacol.* 2018;30(1):1-10. doi: 10.1515/jbcpp-2018-0036, PMID 30063466.
- Tripathi K, Feuerstein JD. New developments in ulcerative colitis: Latest evidence on management, treatment, and maintenance. *Drugs Context.* 2019;8:212572. doi: 10.7573/dic.212572, PMID 31065290.
- Safarpour AR, Kaviyani F, Sepehrihanesh M, Ahmadi N, Koohi Hosseinabadi O, Tanideh N, et al. Antioxidant and anti-inflammatory effects of gel and aqueous extract of *Melilotus officinalis* L. in Induced Ulcerative Colitis: A Rattus norvegicus Model *Ann Color Res.* 2015;3(2). doi: 10.17795/acr-29511.

- Tanideh N, Bahrani M, Khoshnood-Mansoorkhani MJ, Mehrabani D, Firoozi D, Koohi-Hosseinabadi O, et al. Evaluating the effect of *Melilotus officinalis* L. aqueous extracts on healing of acetic acid-induced ulcerative colitis in male rats. *Ann Color Res.* 2016;4(4). doi: 10.17795/acr-42856.
- Tanideh N, Sadeghi F, Amanat S, Firoozi D, Noorafshan A, Iraj A, et al. Protection by pure and genistein fortified extra virgin olive oil, canola oil, and rice bran oil against acetic acid-induced ulcerative colitis in rats. *Food Funct.* 2020;11(1):860-70. doi: 10.1039/c9fo01951k, PMID 31942583.
- Asgarpanah J, Kazemivash N. Phytochemistry, pharmacology and medicinal properties of *Carthamus tinctorius* L. *Chin J Integr Med.* 2013;19(2):153-9. doi: 10.1007/s11655-013-1354-5, PMID 23371463.
- Hoang NQV, Jie K, Ahmad N, Xintong M, Xinyue Z, Yuhang W, et al. Genome-wide identification and expression profiling of duplicated flavonoid 3'-hydroxylase gene family in *Carthamus tinctorius* L. *Not Bot Horti Agrobot Cluj-Napoca.* 2021;49(4):12509-. doi: 10.15835/NBHA49412509.
- Sun LP, Shi FF, Zhang WW, Zhang ZH, Wang K. Antioxidant and anti-inflammatory activities of safflower (*Carthamus tinctorius* L.) honey extract. *Foods.* 2020;9(8). doi: 10.3390/foods9081039, PMID 32748813.
- Yao Y, Yao J, Du Z, Wang P, Ding K. Structural elucidation and immune-enhancing activity of an arabinogalactan from flowers of *Carthamus tinctorius* L. *Carbohydr Polym.* 2018;202:134-42. doi: 10.1016/j.carbpol.2018.08.098, PMID 30286986.
- Rahimi P, Asgary S, Kabiri N. Hepatoprotective and hypolipidemic Effects of *Carthamus tinctorius* oil in alloxan-induced Type 1 Diabetic Rats. *J HerbMed Pharmacol.* 2014;3(2):107-11.
- Wang Y, Chen P, Tang C, Wang Y, Li Y, Zhang H. Antinociceptive and anti-inflammatory activities of extract and two isolated flavonoids of *Carthamus tinctorius* L. *J Ethnopharmacol.* 2014;151(2):944-50. doi: 10.1016/j.jep.2013.12.003, PMID 24333963.
- Li XR, Liu J, Peng C, Zhou QM, Liu F, Guo L, et al. Polyacetylene glucosides from the florets of *Carthamus tinctorius* and their anti-inflammatory activity. *Phytochemistry.* 2021;187:112770. doi: 10.1016/j.phytochem.2021.112770, PMID 33873017.
- Hidalgo-Cantabrana C, Algieri F, Rodriguez-Nogales A, Vezza T, Martínez-Cambor P, Margolles A, et al. Effect of a rosy exopolysaccharide-producing *Bifidobacterium animalis* subsp. *Lactis* strain orally administered on dss-induced colitis mice model. *Front Microbiol.* 2016;7(JUN):868. doi: 10.3389/fmicb.2016.00868, PMID 27375589.
- Olamilosoye KP, Akomolafe RO, Akinsomisoye OS, Adefisayo MA, Alabi QK. The aqueous extract of *Ocimum gratissimum* leaves ameliorates acetic acid-induced colitis via improving antioxidant status and hematological parameters in male Wistar rats. *Egypt J Basic Appl Sci.* 2018;5(3):220-7. doi: 10.1016/j.ejbas.2018.05.006.
- Zheng L, Gao ZQ, Wang SX. A chronic ulcerative colitis model in rats. *World J Gastroenterol.* 2000;6(1):150-2. doi: 10.3748/wjg.v6.i1.150, PMID 11819549.
- Kim JJ, Shajib MS, Manocha MM, Khan WI. Investigating intestinal inflammation in DSS-induced model of IBD. *J Vis Exp.* 2012;60(60). doi: 10.3791/3678, PMID 22331082.
- Tarpey MM, Wink DA, Grisham MB. Methods for detection of reactive metabolites of oxygen and nitrogen: *In vitro* and *in vivo* considerations. *Am J Physiol Regul Integr Comp Physiol.* 2004;286(3):R431-44. doi: 10.1152/ajpregu.00361.2003, PMID 14761864.
- Aguilar Diaz De Leon J, Borges CR. Evaluation of oxidative stress in biological samples using the thiobarbituric acid reactive substances assay. *J Vis Exp.* 2020;2020(159). doi: 10.3791/61122, PMID 32478759.
- Saggu S, Sakeran MI, Zidan N, Tousson E, Mohan A, Rehman H. Ameliorating effect of chicory (*Chichorium intybus* L.) fruit extract against 4-tert-octylphenol induced liver injury and oxidative stress in male rats. *Food Chem Toxicol.* 2014;72:138-46. doi: 10.1016/j.fct.2014.06.029, PMID 25010453.
- Pippenger CE, Browne RW, Armstrong D. Regulatory antioxidant enzymes. *Methods Mol Biol.* 1998;108:299-313. doi: 10.1385/0-89603-472-0:299, PMID 9921539.
- Salice M, Rizzello F, Calabrese C, Calandrini L, Gionchetti P. A current overview of corticosteroid use in active ulcerative colitis. *Expert Rev Gastroenterol Hepatol.* 2019;13(6):557-61. doi: 10.1080/17474124.2019.1604219, PMID 30947569.

25. Randhawa PK, Singh K, Singh N, Jaggi AS. A review on chemical-induced inflammatory bowel disease models in rodents. *Korean J Physiol Pharmacol*. 2014;18(4):279-88. doi: 10.4196/kjpp.2014.18.4.279, PMID 25177159.
26. Pulli B, Ali M, Forghani R, Schob S, Hsieh KLC, Wojtkiewicz G, *et al*. Measuring myeloperoxidase activity in biological samples. *PLOS ONE*. 2013;8(7):e67976. doi: 10.1371/journal.pone.0067976, PMID 23861842.
27. Mantovani A, Muzio M, Garlanda C, Sozzani S, Allavena P. Macrophage control of inflammation: Negative pathways of regulation of inflammatory cytokines. *Novartis Found Symp*. 2001;234:120-31; discussion 131. doi: 10.1002/0470868678.ch8, PMID 11199092.
28. Aguirre-Martinez G. Effective biomarkers to assess the toxicity of pharmaceutical residues on marine bivalves. *Pharm Mar Coast Environ*. 2021. doi: 10.1016/b978-0-08-102971-8.00003-2.
29. Oladele JO, Anyim JC, Oyeleke OM, Olowookere BD, Bamigboye MO, Oladele OT, *et al*. *Telfairia occidentalis* mitigates dextran sodium sulfate-induced ulcerative colitis in rats via suppression of oxidative stress, lipid peroxidation, and inflammation. *J Food Biochem*. 2021;45(9):e13873. doi: 10.1111/jfbc.13873, PMID 34331468.
30. Sharma JN, Al-Omran A, Parvathy SS. Role of nitric oxide in inflammatory diseases. *Inflammopharmacology*. 2007;15(6):252-9. doi: 10.1007/s10787-007-0013-x, PMID 18236016.
31. Fusco R, Cirimi S, Gugliandolo E, Di Paola R, Cuzzocrea S, Navarra M. A flavonoid-rich extract of orange juice reduced oxidative stress in an experimental model of inflammatory bowel disease. *J Funct Foods*. 2017;30:168-78. doi: 10.1016/j.jff.2016.12.038.
32. Gillberg L, Varsanyi M, Sjöström M, Lördal M, Lindholm J, Hellström PM. Nitric oxide pathway-related gene alterations in inflammatory bowel disease. *Scand J Gastroenterol*. 2012;47(11):1283-97. doi: 10.3109/00365521.2012.706830, PMID 22900953.
33. Kandhare AD, Raygude KS, Ghosh P, Ghule AE, Gosavi TP, Badole SL, *et al*. Effect of hydroalcoholic extract of *Hibiscus rosa sinensis* Linn. leaves in experimental colitis in rats. *Asian Pac J Trop Biomed*. 2012;2(5):337-44. doi: 10.1016/S2221-1691(12)60053-7, PMID 23569927.
34. Şengül N, Işık S, Aslim B, Uçar G, Demirbağ AE. The effect of exopolysaccharide-producing probiotic strains on gut oxidative damage in experimental colitis. *Dig Dis Sci*. 2011;56(3):707-14. doi: 10.1007/s10620-010-1362-7, PMID 20683661.
35. Kwon DH, Cha HJ, Lee H, Hong SH, Park C, Park SH, *et al*. Protective effect of glutathione against oxidative stress-induced cytotoxicity in RAW 264.7 macrophages through activating the nuclear factor erythroid 2-related factor-2/heme oxygenase-1 pathway. *Antioxidants (Basel)*. 2019;8(4). doi: 10.3390/antiox8040082, PMID 30939721.
36. Shalkami AS, Hassan M, Bakr AG. Anti-inflammatory, antioxidant and anti-apoptotic activity of diosmin in acetic acid-induced ulcerative colitis. *Hum Exp Toxicol*. 2018;37(1):78-86. doi: 10.1177/0960327117694075, PMID 29187079.
37. Jamwal S, Kumar P. Animal models of inflammatory bowel disease. In: *Animal models for the study of human disease*. 2nd ed. 2017. doi: 10.1016/B978-0-12-809468-6.00019-X.
38. Sommansson A, Wan Saudi WS, Nylander O, Sjöblom M. The ethanol-induced stimulation of rat duodenal mucosal bicarbonate secretion *in vivo* is critically dependent on luminal Cl⁻. *PLOS ONE*. 2014;9(7):e102654. doi: 10.1371/journal.pone.0102654, PMID 25033198.

PICTORIAL ABSTRACT



SUMMARY

- This work focused on the remedial effects of hydroalcoholic *Carthamus tinctorius* L. extracts on TNBS mediated ulcerative colitis in Balb/c mice.
- The extracts prompted curative effects against ulcerative colitis through their ability to reduce the clinical manifestation of the disease, suppress lipid peroxidation, inflammation, and oxidative stress. It also enhances the cytoprotective antioxidant enzymes.
- This study indicates the beneficial effect of the *Carthamus tinctorius* L. extracts in the treatment of TNBS-induced ulcerative colitis.

About Authors



Li Zhang is an attending doctor and currently a medical resident in the People's Hospital of Huaiyin, Jinan in the Department of Anorectal. Her area of interest includes Traditional Chinese medicine and studying Anorectal disorders.



Zhongbao Niu has completed his Master's in Shandong University of Traditional Chinese Medicine and is currently working in the Shandong Provincial Hospital affiliated with Shandong First Medical University. His research mainly focuses on traditional Chinese medicine, anorectal disease drug treatment, and integrated Chinese and Western medicine surgical treatment.

Cite this article: Niu Z, Zhang L. Hydroalcoholic *Carthamus tinctorius* L. Extract Attenuates TNBS-induced Ulcerative Colitis in Mice Via Downregulation of Inflammation and Oxidative Stress. *Indian J of Pharmaceutical Education and Research*. 2022;56(3):780-8.