

Chemo Preventive Effect of Rutin Against N-Nitrosodiethylamine-Induced and Phenobarbital-Promoted Hepatocellular Carcinoma in Wistar Rats

Yadala Prapurna Chandra, A.H.M. Viswanathswamy

K.L.E university's college of pharmacy, Vidyanagar, Hubli-580031, Karnataka, INDIA.

ABSTRACT

Background: In recent years, a large number of natural compounds have been identified and proved to have a potential cancer chemopreventive importance due to their strong antioxidant and cytotoxic activities. **Objective:** The present study is designed to investigate the preventive effects of Rutin against N-Nitrosodiethylamine-induced and Phenobarbital-promoted Hepatocellular carcinoma in male wistar rats. **Materials and Methods:** Twenty-four male wistar rats were divided into four groups (n=6). Group I serve as Control, Group II was induced HCC by DEN (200mg/kg b.wt) followed by phenobarbital (0.05 % w/v), Group III received same as Group II and followed by Rutin (50mg/kg b.wt) and Group IV received Rutin alone at a dose of 50mg/kg b.wt, up to 16 successive weeks. **Results:** Results observed that there is significant increase in relative liver weight and liver marker enzymes ($P < 0.001$), tumor marker enzymes (AFP, CEA at $P < 0.001$) and also Significant abnormalities were observed in membrane bound enzymes and Electrolytes, whereas the above said alterations were significantly restored in Rutin treated group compared with DEN treated Group. **Conclusion:** The results of these findings suggested that Rutin can be used as an adjunct to conventional chemopreventive agent, which may provide a novel therapeutic approach to serve as a promising agent for treatment of Hepatocellular carcinoma.

Key words: Hepatocellular Carcinoma, Rutin, N-Nitrosodiethylamine, Phenobarbital, α -fetoprotein, Carcinoembryonic antigen.

Key Messages

- This study reports the effect of Rutin in Hepatocellular carcinoma, Rutin significantly reduced the levels of cancer markers, biochemical markers and Histopathological parameters in HCC rat models.
- Also Rutin shows significant effect on restoring body weight, food intake and controls the electrolyte imbalance in experimental rats.
- Eventually Rutin evoked a significant protective effect on HCC induce by DEN

INTRODUCTION

Hepatocellular carcinoma (HCC), also called malignant hepatoma is the most common primary liver cancer, which accounts as the third leading cause of deaths worldwide.¹ HCC is a fatal malignancy extends in several regions of Africa and Asia (80%).² The majority of HCC cases attributable to prime infections is induced by hepatitis B and C viruses, aflatoxin exposure, liver cirrhosis, environmental pollutants like nitrosamines

and obesity. The current treatment for HCC is employed by several modalities. Potentially the beneficial options for HCC is liver transplantation or local ablation are considered when the tumor is restricted to the liver. But, these therapies not only confine to the extent of tumor, but also by the liver disease and circumstance of the patient.^{3,4} In recent years, many natural compounds and herbs have increasingly been receiving

Submission Date: 25-02-2017;
Revision Date: 26-05-2017;
Accepted Date: 29-09-2017

DOI: 10.5530/ijper.52.1.9

Correspondence:

AHM. Vswanathswamy,
K.L.E university's college
of pharmacy, Vidyanagar,
Hubli-580031, Karnataka,
INDIA.
Phone no: 9502949797;
E-mail: vmhiremath2004@
gmail.com



www.ijper.org

public interest by its potent therapeutic action as a complementary and alternative medicine.⁵ A number of studies have proved that flavonoids and phenolics have wide range of physiological functions due to their potent anti-oxidant activity.⁶ Rutin (3',4',5,7-tetrahydroxy-flavone-3-rutinoside) (Figure 1a), a common dietary flavonoid with a wide range of pharmacological activities is present in many plants (as buckwheat seeds, tea), fruits (citrus fruits, apple), vegetables (onion), and red wine etc.⁷ Different studies have represented the biological effects of Rutin, such as anti-oxidative, anti-inflammatory, antihypertensive, anti-carcinogenic, cytoprotective, and cardio protective activities.⁸

N-Nitrosodiethylamine (DEN) Structure showed in Figure 1b is found in the environment, and it is present in foods, beverages, tobacco, smoke, agricultural chemicals, cosmetics and industrial pollution. These are the major risk factors of liver diseases, and their endogenous formations causes a wide range of tumors, and dangerous to human health. DEN is called to be human carcinogen based on the sufficient evidence of carcinogenicity in experimental animal models.^{9,10} it is known to cause disturbance in course or arrangement in the nuclear enzymes involved in DNA repair/replication. The reactive oxygen species (ROS) formation occurs during the metabolic biotransformation of nitrosamines and leads to carcinogenesis by up regulation of biochemical, intracellular signalling pathways and gene expression. One of the most important applications in the emerging field of cancer treatment is to discover the alternative therapy for solid tumors with negligible cytotoxicity to the normal cells. Hence, the identification of novel compound from plant origin especially have been shown as the chemotherapeutic agent. Thus, the bioactive compound provides a better opportunity to improve the present standard of care for HCC and other cancers.^{11,12} There is no evidence for anticancer activity of Rutin against nitrosamine induced hepatocellular carcinoma. The present study was designed with the aim of investigation of anti-cancer activity of Rutin against DEN induced and phenobarbital promoted HCC in Male wistar Rats.

MATERIALS AND METHODS

Chemicals

Rutin and N-Nitrosodiethylamine (DEN) were purchased from Sigma Aldrich co. (Bangalore, India). Kits for liver pathophysiological markers were procured from Erba Mannheim. SP twin electrolytes, calcium and Magnesium kits were procured from Span diagnostics Ltd. ATP (Adenosine triphosphate) was purchased from Hi

Media Pvt. Ltd. (Mumbai). All other chemicals used in this study were analytical grade from SD Fine chemicals.

Experimental animals

Wistar albino pathogen-free male rats weighing 100-150g were obtained from Sri Venkateshwara Enterprises, Bangalore. The animals were housed in polypropylene cages with husk bedding under standard laboratory conditions (temperature 25°C ± 2°C, and 50 ± 10 % relative humidity and 12 hours dark/light cycle). The animals were fed with standard pelleted diet and drinking water was provided *ad libitum*. Before starting of experiment, animals were acclimatized to the animal room conditions for one week. The experiment was designed and conducted with adherence to the ethical guidelines regulated by the Committee for the Purpose of Control and Supervision of Experiments on Animals (CPCSEA) and study was reviewed and approved (Ref No :08/Mar-14) by the Institutional Animal Ethics Committee. The rats were randomly divided into four groups, each group containing six animals (n=6) as depicted in Table 1 and Figure 2.

Collection of Blood

At the end of the treatment period blood was collected with deep inhalation anaesthesia by use of isoflurane, blood samples were collected by retro orbital puncture and allowed to clot for one hour at room temperature. Centrifuge at 4000 rpm for 15 min, to separate serum and analyzed the same for the following observations.

Biochemical studies

Serum was separated and levels of aspartate aminotransferase (AST), alanine aminotransferase (ALT), acid phosphatase (ACP), alkaline phosphatase (ALP), lactate dehydrogenase (LDH), gamma glutamyltransferase (γ -GT) and total bilirubin (TBIL) were estimated using an automated ERBA biochemical analyzer. The total protein in the serum was estimated by Lowry's method¹⁷ and quantification of DNA was estimated by using QIAGEN kit.

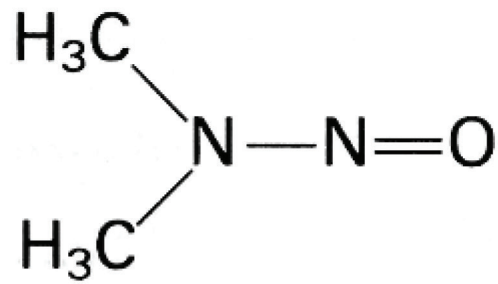
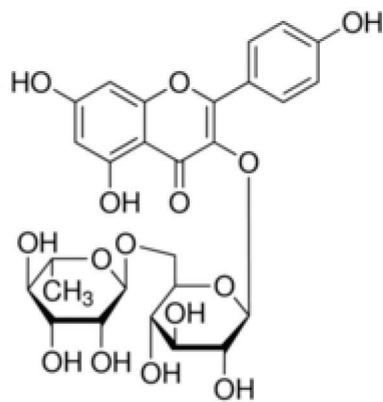
Enzyme linked immunosorbant assay (ELISA) of AFP and CEA

The quantitative estimation of liver tumor markers α -fetoprotein (AFP) and carcinoembryonic antigen (CEA) was monitored based on solid phase enzyme linked immunosorbant assay (ELISA).^{18,19}

Estimation of Membrane bound enzymes

Na⁺ K⁺ ATPase was estimated by the method of Bonting.²⁰ The activity of Ca²⁺ ATPase was assayed

Table 1: Experimental design and treatment protocol		
Groups	Treatment	Study period
Group I - Normal control	Receives only 0.9% w/v normal saline daily for 16 weeks. ¹²	16 Weeks
Group II-Disease control	Received DEN at a single dose of 200 mg/kg (body weight) intraperitoneally on 1 st week followed by administration of phenobarbital (PB) (0.05% w/v) daily after 2 nd week through drinking water up to 16 successive weeks. ^{13,14}	
Group III-Treatment group	Received DEN at a single dose of 200 mg/kg (body weight) intraperitoneally on 1 st week followed by administration of Phenobarbital (PB) (0.05% w/v) daily after 2 nd week through drinking water up to 16 weeks. Rutin was given orally after 2 nd week at a dose of 50 mg/kg, ^{15,16} (body weight) up to 16 successive weeks.	
Group-IV-Rutin Only	Received Rutin orally after 2 nd week at a dose of 50 mg/kg (body weight) up to 16 successive weeks.	



a) Rutin (3',4',5,7-tetrahydroxy-flavone-3-rutinoside), b) N-Nitrosodiethylamine (DEN)

Figure 1: Chemical structure of (a) Rutin,⁷ (b) N-Nitrosodiethylamine (DEN).^{9,10}

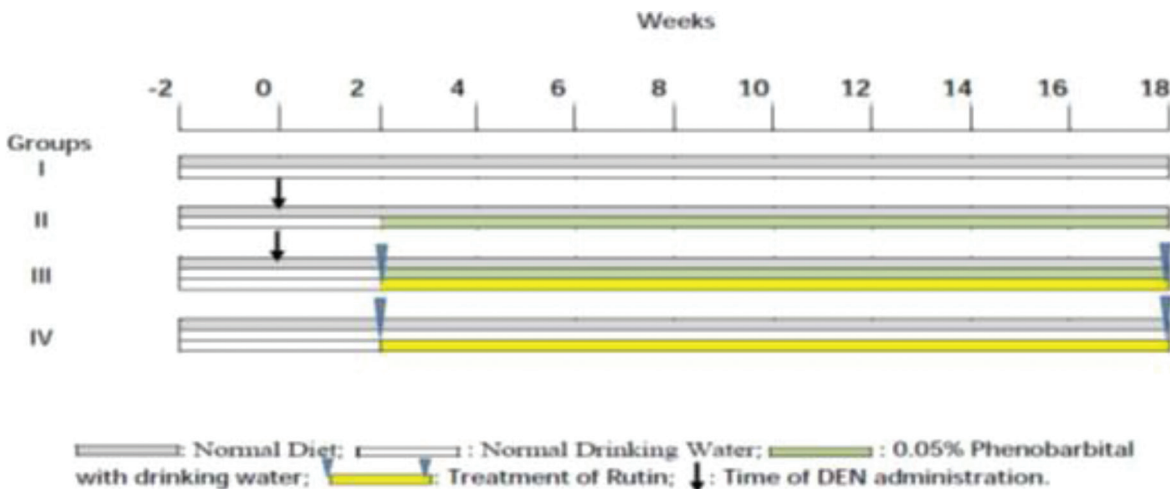


Figure 2: Schematic representation of the experimental protocol involving DEN exposed experimental rat hepatocellular carcinogenesis.

by the method of Hjerten and Pan.²¹ The activity of Mg^{2+} ATPase was assayed by the method of Ohnishi *et al.*²²

Estimation of Electrolytes

The concentration of Sodium and Potassium in serum were estimated by Gilbert's method. Concentration of calcium in serum was estimated by Stein *et al.*²³ and serum magnesium concentration was estimated by Gindler's method.²⁴

Histopathological studies²⁵

A portion of the liver was cut into 2-3 pieces of approximately 6 mm size and fixed in phosphate buffered 10% formaldehyde solution. After embedding in the paraffin wax, thin sections of 5 μ m thickness of liver tissues were cut and stained with Haematoxyllin- Eosin staining. The thin sections of liver were made into permanent slides and examined under high resolution microscope with photographic facility.

Statistical analysis

The data was computed by using Graph Pad Prism Software version 5.0. The statistical significance was analyzed by using one-way ANOVA followed by Bonferroni's multiple comparison test. P values < 0.05 were considered to indicate statistical significance. All the results were expressed as mean \pm SEM for six animals in each group.

RESULT

General observations

Experimental rats were well tolerated Intraperitoneal and oral administration of DEN and PB respectively, and there were no clinical signs of toxicity-related death in the groups during the experimental period, there was a moderate change in food and water consumption and mild difference in growth rates of control and treatment groups, the data on mean body weight, liver weight and relative liver weight were summarized in Table 2.

The relative liver weight of DEN administered rats was significantly ($p < 0.001$) increased as compared with control group and Rutin treated group showed significant ($p < 0.001$) reduction in the relative liver weight compared with DEN administered rats.

Biochemical studies

Effect of Rutin on liver marker enzymes like AST, ALT, ALP, LDH, γ -GT and ACP, TBIL, DNA, Total protein in the serum of control and experimental groups of rats as shown in Figure 3 and Table 3 respectively. Compari-

sons were made as *** statistical significant at $P < 0.001$, compared with Normal group; ### statistical significant at $P < 0.001$ compared with DEN/PB group; ns: non-significant compared with DEN/PB group.

The DEN administered (Group II) rats reflects significant ($P < 0.001$) elevation in the liver cell metabolism, which leads to distinctive changes in liver marker enzymes when compared with normal control (Group I) rats. Increased enzymes levels are indicators of liver damage. The treatment groups of Rutin (Group III) showed significant ($P < 0.01$, $P < 0.05$) decrease in the activities of these enzymes when compared with DEN induced group rats. However, the status of these marker enzymes in Rutin alone (Group IV) administered groups does not exhibit any significant alterations compared to the normal control group which indicates the non-toxic nature of Rutin.

Enzyme linked immunosorbant assay (ELISA) of AFP and CEA

Alfa fetoprotein and Carcinoembryonic antigens are the most extensive tumor markers used in the diagnosis of HCC. Therefore, high levels of AFP and CEA are believed to be a strong indicator of hepatic carcinogenesis because more than 80% of HCC patients have high serum concentration of AFP and CEA due to tumor burden. The levels of AFP and CEA in DEN administered (Group, II) rats were increased significantly ($p < 0.001$) compared with normal control (Group, I) rats, which could be due to tumor cell proliferation. However, the levels of these tumor markers were significantly ($p < 0.001$) abridged in Rutin treated group (Figure 4), which was presumably due to inhibition of malignant transformation and therefore, decreases in the tumor production rates that are associated with anti-proliferative effect.

Comparisons were made as *** statistical significant at $P < 0.001$ compared with Normal group; ### statistical significant at $P < 0.001$, compared with DEN/PB group.

Estimation of Membrane bound enzymes

Figure 5 represents; DEN treatment group (Group-II) caused significant ($P < 0.001$) reduction in the activities of Ca^{2+} ATPase, Na^{+}/K^{+} ATPase and Mg^{2+} ATPase in the liver tissue of rats as compared to control (Group-I), whereas rutin treated group (Group-III) was shown mild elevation of Ca^{2+} ATPase, Na^{+}/K^{+} ATPase and shown significant ($P < 0.001$) elevation in Mg^{2+} ATPase. Comparisons were made as *** statistical significant at $P < 0.001$ compared with Normal group; ### statistical significant at $P < 0.001$ compared with DEN/PB group; ns: non-significant compared with DEN/PB group

Group	Rat initial weight (in grams)	Rat final weight (in grams)	Liver weight (in grams)	Relative liver weight
Group I	140.83 ± 3.52	317.50 ± 9.98	12.0 ± 0.51	3.8 ± 0.12
Group II	171.67 ± 4.94	251.67 ± 11.45	13.7 ± 0.36	5.5 ± 0.18***
Group III	170.00 ± 4.28	245.00 ± 6.58	10.8 ± 0.20#	4.4 ± 0.10#
Group IV	148.83 ± 5.29	301.67 ± 5.87	12.0 ± 0.47	4.0 ± 0.20

Results were expressed as Mean ± SEM (n = 6), Comparisons were made as *** statistical significant at P< 0.001, compared with Normal group. # Statistical significant at P< 0.05, compared paired with DEN/PB group.

	Group I	Group II	Group III	Group IV
ACP (mgs%)	1.66 ± 0.41	3.61 ± 0.74***	3.46 ± 0.42ns	2.89 ± 0.55
TBL (mgs%)	0.46 ± 0.11	1.43 ± 0.21***	0.77 ± 0.04#	0.66 ± 0.08
DNA (µg/ml)	39.60 ± 2.54	339.17 ± 28.98***	239.99 ± 10.53##	38.30 ± 2.53
T. Proteins (mgs%)	7.73 ± 0.41	3.09 ± 0.74***	5.14 ± 0.50##	7.77 ± 0.39

Values are expressed as Mean ± SEM (n=6), by one-way ANOVA followed by Bonferroni test. Where ***p< 0.001 significant compared with normal group, and ## p< 0.01, # p< 0.05, and ns: non-significant, compared with DEN/PB group, respectively.

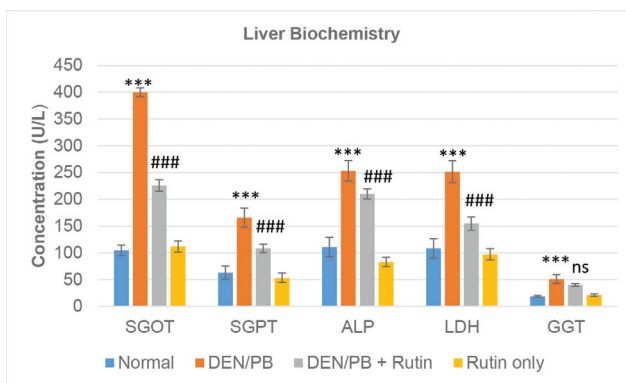


Figure 3: Liver biochemistry.

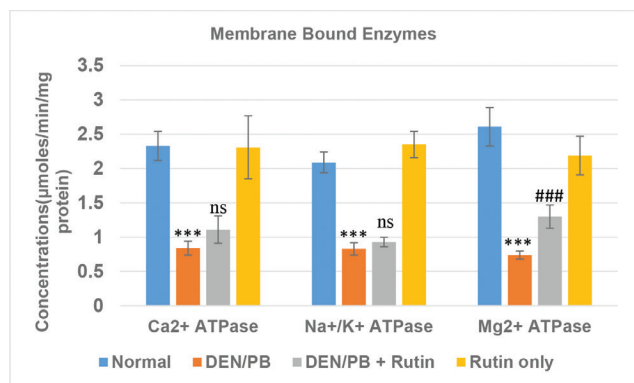


Figure 5: Membrane bound enzymes

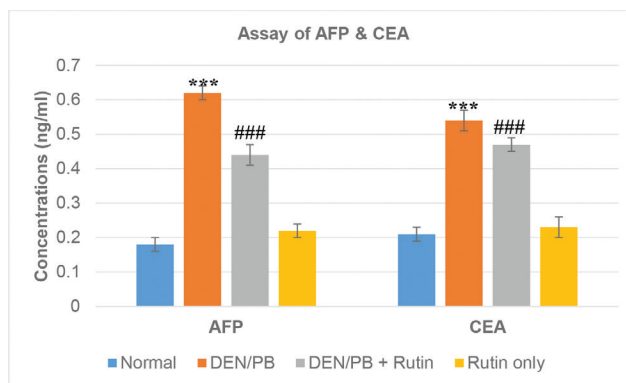


Figure 4: Assay of AFP & CEA

Estimation of Electrolytes

Electrolytes such as serum potassium, calcium and magnesium concentrations were significantly (P< 0.001) increased in Group II compared with control group (Group, I) and significant (P<0.001) reduction in the serum sodium concentrations were observed, which indicates the fluid and electrolyte imbalance in the DEN treated group (Group, II) compared with the normal group (Group, I). Rutin treated group shown (Group III) significant reduction in serum potassium, calcium and magnesium concentrations (P<0.001, P<0.001 and P<0.05 respectively), and deflation serum sodium levels compared with the DEN treated group (Group, II). Results are shown in Table 4.

Liver histopathology

Figure 6, Depicts that Anti-cancer activity of Rutin against DEN/PB induced rats. Photomicrographs

Table 4: Estimation of Electrolytes

	Group I	Group II	Group III	Group IV
Sodium (mEq/L)	146.27 ± 2.83	92.20 ± 3.49***	124.74 ± 7.14 [#]	146.22 ± 8.16
Potassium (mEq/L)	6.01 ± 0.43	10.94 ± 0.49***	6.75 ± 0.22***	5.12 ± 0.30
Calcium (mgs%)	6.12 ± 0.89	14.59 ± 1.21***	10.62 ± 1.12***	6.04 ± 0.70
Magnesium (mgs%)	5.62 ± 0.52	10.71 ± 0.45***	7.98 ± 0.67 [#]	5.17 ± 0.56

Values are expressed as Mean ± SEM (n=6), by one-way ANOVA followed by Bonferroni test. Where *** $p < 0.001$, significant compared with normal group, and *** $p < 0.001$, [#] $p < 0.05$, compared with DEN/PB group respectively.

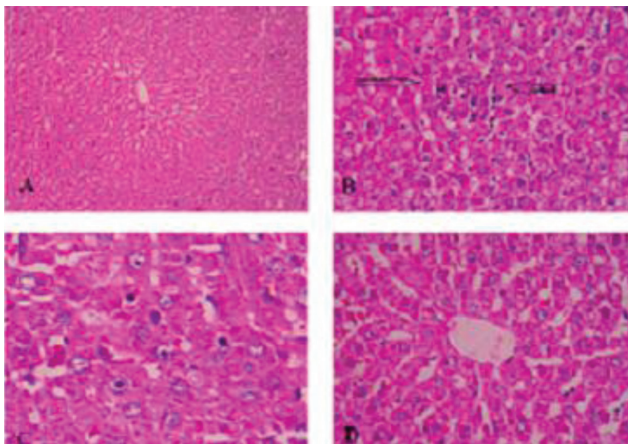


Figure 6: Photomicrographs of (H & E staining) Histopathological studies of Liver of various groups.

(40 X magnification) of liver section taken from different groups. 6(A), Control group (Group I) shows normal lobular architecture and normal hepatocytes. 6(B) DEN/PB treatment group (Group II) shows focal necrosis and inflammation in the liver (marked in arrows) and hepatocellular degeneration by DEN. 6 (C) DEN/PB + Rutin treatment group (Group III) depicts improvements in the architecture with lesser damage of hepatocytes and low index of necrosis. 6 (D) Rutin only treatment group (Group IV) shows normal lobular architecture and normal hepatocytes.

DISCUSSION

Uncontrolled proliferation is one of the main characteristic mechanisms for tumorigenesis which acquires at different stages of cancer development. Like initiation, promotion and progression of tumor growth, thereby increasing the tumor burden and initiating metastasis,²⁶ this dysregulation mainly occurred by disrupted G1/S phase cell cycle transmission during the development of malignant neoplasm; therefore, the present study was conducted to evaluate the anti-proliferative activity of

Rutin through modulating the cell cycle regulator proteins during DEN induced rat HCC.

In the present study, the food, water intake and the body weight of control and experimental rats were monitored. The body weight of DEN administered rats was significantly lowered, and this unintentional weight loss was derived from loss of both muscle mass and fat mass. An increased liver weight in HCC induced animals indicate an uncontrolled proliferation of the cancer cells, there by increased tumor mass and liver weight observed as a common symptom of carcinogenesis.²⁷ In contrast, Rutin treated groups, significantly improved body weight with reduced liver weight, which indicates Rutin has suppressed the tumor in DEN induced HCC rats.

In this study, the liver marker enzymes AST, ALT, ALP, ACP, LDH, γ -GT, T.Protein and T.BIL levels exceeded their normal range in DEN/PB treated group, compared with normal control group indicating the carcinogenic nature of DEN, Which may be due to metabolic dysfunction of liver and this is due to leakage of these enzymes from liver cytosol into blood.²⁸ In Rutin treated group, the activity of hepato specific enzymes were restored near to the normal levels which demonstrates the effect of Rutin in prevention of DEN induced uncontrolled proliferation and dysregulation of cell proliferation.

The tumor markers AFP and CEA are associated with cancer, and these are useful in the diagnosis and progression of cancer. The combinations of serological analysis of AFP and CEA are being considered as a most extensively used in the diagnostic and prognostic determinant value for HCC.²⁹ AFP is one of the most sensitive and specific marker for diagnosis of cancer, the increased levels of AFP observed in acute and chronic viral hepatitis due to proliferation of hepatocytes.³⁰ Elevation of CEA occurred in the terminal stage of incurable cancer like HCC. In this study, AFP and CEA levels were drastically increased in the DEN administered rats compared

to the normal group, which indicates the progression of HCC. Our results suggested that levels of AFP and CEA were significantly lowered in the Rutin treatment group when compared with DEN induced group, which clearly states that Rutin may inhibit the aberrant tumor production and metastasis resulting in the inhibition of uncontrolled cell proliferation in tumor cells.

Quantification of DNA levels in liver is a potential biomarker for tumor diagnosis and prognosis. Increased levels of DNA levels were observed in DEN treated group indicates uncontrolled DNA replication due to formation of reactive oxygen species (ROS).³¹ In treatment group shows, reduced levels of DNA indicated its ability to reduce the tumor proliferation.

Membrane-bound enzymes and electrolytes are also specific indicators for hepatocellular carcinoma.³² The membrane-bound enzymes such as Na^+/K^+ , Ca^{2+} and Mg^{2+} ATPase is responsible for transport of sodium, potassium and calcium ions across membrane.³³ In the present study the levels of Na^+/K^+ ATPase was found to decrease in erythrocyte, membranes of liver and decreased Mg^{2+} ATPase was observed in DEN treated animals, this is may be due to increased lipid peroxidation (LPO) and membrane damage by DEN. However, Rutin treated group improved these ATPase levels near to the normal values. It indicates that Rutin can protect the structural integrity and probably shield against the deleterious effect of lipid peroxidation. Primary liver tumor may present as a hypercalcemia crisis and the finding of elevated serum calcium levels is indicative of liver failure. Furthermore, failure of sodium pump results in a depletion of plasma sodium and rise in plasma potassium concentration, which are the most common electrolyte abnormalities in cancer conditions.^{34,35}

Magnesium is directly implicated as the key element in controlling proliferation of both normal and neoplastic cells. A rapid influx of magnesium is observed at cell division, and high intracellular magnesium levels may operate to promote cell division. Elevated levels of intracellular magnesium would then accelerate cellular mitosis. Thus in cancer, the intracellular free magnesium concentration is higher than that in normal cells^{36,37} in Rutin treated group it was observed that the restoration of these electrolytes near to the normal range indicates effectiveness of Rutin in restoration of membrane stability may be responsible for the recovery of mineral status in HCC suffering animals, which explains the anti-cancer activity of Rutin against DEN induce HCC.

CONCLUSION

Based upon the above results, we can conclude that the data provides strong evidence that inhibition of

cell proliferation in neoplastic hepatocytes and hepatic tissue by Rutin is a major mechanism that may be due to inhibition of hepatocarcinogenesis. This inhibition might lead to suppression of the hepatospecific marker enzymes, tumor invasion. Furthermore, Rutin shows its definite modulating effect on cell membranes and on the deregulated mineral status. Hence Rutin can be used as an adjunct to conventional chemo preventive agent, which may provide a novel therapeutic approach to serve as promising agent for treatment of Hepatocellular carcinoma in future.

ACKNOWLEDGEMENT

The author are great full to the KLE University and VGST, Govt. of Karnataka for providing required facilities to carry out this study.

CONFLICT OF INTEREST

Author declared as none.

ABBREVIATIONS USED

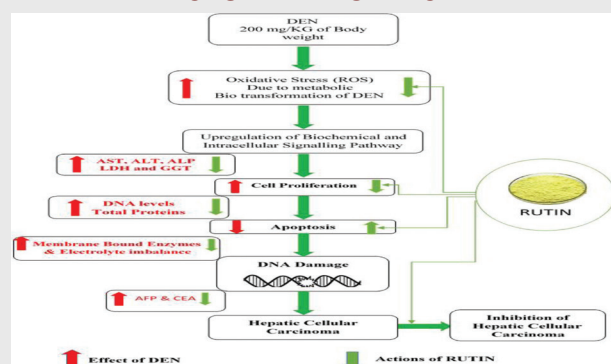
HCC: Hepatocellular carcinoma; **DEN:** N-Nitrosodiethylamine; **ROS:** Reactive oxygen species; **CPCSEA:** Committee for the Purpose of Control and Supervision of Experiments on Animals; **AST:** Aspartate aminotransferase; **ALT:** Alanine aminotransferase; **ACP:** Acid phosphatase; **ALP:** Alkaline phosphatase; **LDH:** lactate dehydrogenase; **γ -GT:** Gamma glutamyltransferase; **TBIL:** Total bilirubin; **AFP:** α -fetoprotein; **CEA:** carcinoembryonic antigen; **ELISA:** Enzyme linked Immunosorbant Assay; **ANOVA:** Analysis of variance; **SEM:** Standard error mean.

REFERENCE

1. Ferenci P, Fried M, Labrecque D, Bruix J, Sherman M. Hepatocellular carcinoma (HCC): a global perspective. *J ClinGastroenterol.* 2010;44(4): 239-45.
2. Gomaa AI, Khan SA, Toledano MB, Waked I, Taylor-Robinson SD. Hepatocellular carcinoma: epidemiology, risk factors and pathogenesis. *World journal of gastroenterology: WJG.* 2008;14(27):4300.
3. Wildi S, Pestalozzi BC, McCormack L, Clavien PA. Critical evaluation of the different staging systems for hepatocellular carcinoma. *British journal of surgery.* 2004;91(4):400-8.
4. Mathew S, Faheem M, Suhail M, Fatima K, Archunan G, *et al.* Updates on Traditional Medicinal Plants for Hepatocellular Carcinoma. *Pharmaceutical Journals.* 2016;8(3).
5. Carnat AP, Carnat A, Fraise D, Lamaison JL, Heitz A, *et al.* *Journal of natural products.* 1998;61(2):272-4.
6. Buszewski B, Kawka S, Suprynowicz Z, Wolski T. Simultaneous isolation of rutin and esculin from plant material and drugs using solid-phase extraction. *Journal of pharmaceutical and biomedical analysis.* 1993;11(3):211-5.
7. Chen SS, Gong J, Liu FT, Mohammed U. Naturally occurring polyphenolic antioxidants modulate IgE-mediated mast cell activation. *Immunology.* 2000;100(4):471-80.

8. Novakovic A, Gojkovic-Bukarica L, Peric M, Nezic D, Djukanovic B, *et al.* The mechanism of endothelium-independent relaxation induced by the wine polyphenol resveratrol in human internal mammary artery. *Journal of pharmacological sciences*. 2006;101(1):85-90.
9. Perz JF, Armstrong GL, Farrington LA, Hutin YJ, Bell BP. The contributions of hepatitis B virus and hepatitis C virus infections to cirrhosis and primary liver cancer worldwide. *Journal of hepatology*. 2006;45(4):529-38.
10. Smith CJ, Livingston SD, Doolittle DJ. An international literature survey of "IARC Group I carcinogens" reported in mainstream cigarette smoke. *Food and Chemical Toxicology*. 1997;35(10):1107-30.
11. Ramakrishnan G, Augustine TA, Jagan S, Vinodhkumar R, Devaki T. Effect of silymarin on N-nitrosodiethylamine induced hepatocarcinogenesis in rats. *Exp Oncol*. 2007;29(1):39-44.
12. Newman DJ. Natural products as leads to potential drugs: an old process or the new hope for drug discovery?. *Journal of medicinal chemistry*. 2008;51(9):2589-99.
13. Gayathri R, Kalpana DP, Gunassekaran GR, Dhanapal S. Protective role of ursolic acid in den induced oxidative stress mediated hepatocellular carcinoma a focus on thiol status. *Int J Pharm Pharm Sci*. 2010;2:140-6.
14. Sivalokanathan S, Ilayaraja M, Balasubramanian MP. Antioxidant activity of Terminalia arjuna bark extract on N-nitrosodiethylamine induced hepatocellular carcinoma in rats. *Molecular and cellular biochemistry*. 2006;281(1):87-93.
15. Kamalakkannan N, Prince PS. Rutin improves the antioxidant status in streptozotocin-induced diabetic rat tissues. *Molecular and cellular biochemistry*. 2006;293(1):211-9.
16. Khan RA, Khan MR, Sahreen S. CCl 4-induced hepatotoxicity: protective effect of rutin on p53, CYP2E1 and the antioxidative status in rat. *BMC complementary and alternative medicine*. 2012;12(1):178.
17. Lowry OH, Rosebrough NJ, Farr AL, Randall RJ. Protein measurement with the Folin phenol reagent. *Journal of biological chemistry*. 1951;193(1):265-75.
18. Benassayag C. Alpha-fetoproteine: purification, caracteristiques physico chimiques et proprietes de liaison. Forest MG and Pugeat M.EDS Binding Proteins of Steroid Hormones. Colloque INSERM. John LibbeyEurotext Ltd. 1986;149:53-68.
19. ZamcheckN. *Adv Intern Med*. 1974;19:413
20. Bonting SL. Sodium-potassium activated adenosine triphosphatase and cation transport. *Membranes and ion transport*. 1970;1:257-363.
21. Hjertén S, Pan H. Purification and characterization of two forms of a low-affinity Ca²⁺-ATPase from erythrocyte membranes. *Biochimica et Biophysica Acta (BBA)-Biomembranes*. 1983;728(2):281-8.
22. Ohnishi T, Suzuki T, Suzuki Y, Ozawa K. A comparative study of plasma membrane Mg²⁺-ATPase activities in normal, regenerating and malignant cells. *Biochimica et Biophysica Acta (BBA)-Biomembranes*. 1982;684(1):67-74.
23. Stone GC, GOLDZIBHBE J. A rapid colorimetric method for the determination of sodium in biological fluids and particularly in serum. *Journal of Biological Chemistry*. 1949;181:511-21.
24. Stein J. *ClinicaChimicaActa*. 1957;2:576.
25. Gindler E. *Clinical Chemistry*. 1971;17:662.
26. Gupta SC, Kim JH, Prasad S, Aggarwal BB. Regulation of survival, proliferation, invasion, angiogenesis, and metastasis of tumor cells through modulation of inflammatory pathways by nutraceuticals. *Cancer and Metastasis Reviews*. 2010;29(3):405-34.
27. Naveen Kumar C, Asok Kumar S, Raghunandhakumar S, Jagan, P.Anandakumar S, *et al.* Devaki. Potent antitumor and antineoplastic efficacy of baicalein on benzo (a) pyrene-induced experimental pulmonary tumorigenesis. *FundamClinPharmacol* 2012;26:259-70.
28. Ramakrishnan G, Augustine TA, Jagan S, Vinodhkumar R, Devaki T. Effect of silymarin on N-nitrosodiethylamine induced hepatocarcinogenesis in rats. *Exp Oncol*. 2007;29(1):39-44.
29. Gong L, Zheng M, Li Y, Zhang W, Bu W, *et al.* Seminal vesicle metastasis after partial hepatectomy for hepatocellular carcinoma. *BMC cancer*. 2011;11(1):111.
30. Davis GL, Dempster J, Meler JD, Orr DW, Walberg MW, *et al.* Hepatocellular carcinoma: management of an increasingly common problem. *Proceedings (Baylor University. Medical Center)*. 2008;21(3):266.
31. Smith CJ, Livingston SD, Doolittle DJ. An international literature survey of "IARC Group I carcinogens" reported in mainstream cigarette smoke. *Food and Chemical Toxicology*. 1997;35(10):1107-30.
32. Bioj, B. Moreto, RD and Fairs RN. Membrane lipid fatty acid and regulation of membrane bound enzymes, *Biochem. Biophys. Acta* 1973;31(1):67.
33. Stekhoven FS, Bonting SL. Transport adenosine triphosphatases: properties and functions. *Physiological Reviews*. 1981;61(1):1-76.
34. Skou, N. Spatial orientation of the Na⁺⁺K⁺ dependent enzymatic reaction in the cell membrane, in *Biomembranes*, Vol. 2, ed. by Manson, L.A. Plenum Press, New York. 1971;2:165-86.
35. Hickie, A. and Galent, H. Calcium and magnesium content of rat liver and Morris hepatoma 5123. *Cancer Res*. 1967;27:1053-57.
36. Hickie RA, Kalant H. Calcium and magnesium content of rat liver and Morris hepatoma 5123 tc. *Cancer research*. 1967;27(6 Part 1):1053-7.
37. Walker, G.M. Accumulation of magnesium ions during the cell cycle, in *Cell Membranes and Cancer*, ed. by Galeotti, T. Cittadini, A. Nevi, G. Papa, S. and Smets, L.A. Elsevier Science Publishers, North Holland. 1985;161-7.

PICTORIAL ABSTRACT



SUMMARY

Study was aimed to evaluate the potential effect of Rutin in DEN induced hepatocellular carcinoma (HCC), HCC was induced by injecting (200 mg / kg, Through I.P) in male wistar rats and Phenobarbital used as a promotor. Treatment groups were treated with 50 mg / kg p.o. at the end of the study period, all experimental animals were sacrificed and estimated the biochemical parameters, membrane bound enzymes and tumor markers which were significantly elevated compared to normal control group and histopathology studies revealed that the formation of Hepatocellular carcinoma. Rutin treated groups showed significant inhibitory action in progression of hepatocellular carcinoma by restored the all abnormalities compared to DEN treated groups. Hence Rutin shows potent preventive effect on Hepatocellular carcinoma & further investigations required to prove its molecular pharmacological actions.

About Authors



Dr. A H M Viswanath Swamy: Is working as a professor and HOD in the Department of Pharmacy Practice, KLEU's college of pharmacy, Hubballi. He was published more than 40 peer reviewed research articles in the International and National Journals and attended More than 10 National and international Seminars/Conferences. He has been appointed as resource person for QIP Programmes and AICTE sponsored workshops.



Mr Y.Prapurna Chandra: is working as a full time Ph.D scholar in the Department of pharmacology, KLEU's college of pharmacy, Hubballi. He was published 5 peer reviewed research articles in the National Journals and attended More than 10 Seminars/Conferences.

Cite this article: Chandra YP, Viswanathswamy AHM. Chemo Preventive Effect of Rutin Against N-Nitrosodiethylamine-Induced and Phenobarbital-Promoted Hepatocellular Carcinoma in Wistar Rats. Indian J of Pharmaceutical Education and Research. 2018;52(1):78-86.